

Pseudocyst of Pinna and Its Treatment with Surgical Deroofing: An Experience at Tertiary Hospitals

Nazir A. Khan, Mudasir ul Islam¹, Ayaz ur Rehman, Shakeel Ahmad¹

Department of ENT and HNS, SKIMS Medical College,

¹Department of ENT and HNS, Government Medical College, Srinagar, Jammu and Kashmir, India

INTRODUCTION

A pseudocyst of auricle is a rare and benign cystic swelling resulting from intracartilaginous accumulation of fluid. Engel^[1] was the first to describe the condition as “auricular pseudocyst”. The scaphoid fossa, triangular fossa of the antihelix, and the cymba concha are typically involved. Various terms for this condition are endochondral pseudocyst, intracartilaginous auricular seroma cyst, cystic chondromalacia, and benign idiopathic cystic chondromalacia.^[2] Males are commonly affected and the mean age of presentation is 35-40 years. The majority of the pseudocysts are unilateral lesions.^[2] Usually these cysts are asymptomatic but occasionally, minor discomfort and mild inflammatory signs may be present. The size of the cyst ranges from 1 to 5 cm in diameter and contains viscous straw-yellow fluid while sometimes a clear pale yellow may be encountered.^[2] The etiology of this condition is unknown but at the same time many investigators believe that repeated minor injuries were responsible for the formation of pseudocysts, particularly in patients with preexisting congenital intracartilaginous defects associated with lymphatic and vascular channels while some believe that the cause is cartilaginous degeneration caused by the release of chondrocyte lysosomal enzymes.^[3] Diagnosis is based on the clinical characteristics and no evidence of infection. The

ABSTRACT

Introduction: Pseudocyst of pinna is an uncommon condition hardly encountered in routine ENT practice. The involvement is usually seen in scaphoid, triangular fossa, and antihelix. Medical treatment is ineffective. Various treatments are suggested in the literature. The aims of the paper were to study the clinical characteristic of patients with pseudocysts and to share our experience with surgical deroofing and buttoning as a definitive treatment. **Materials and Methods:** Twenty-six patients were diagnosed with pseudocyst of the auricle between April 2011 and 2013 in two medical college hospitals. Clinical characteristics were noted. All patients underwent incision and drainage with removal of anterior cartilage leaflet followed by buttoning for 12 days. **Results and Observations:** Out of 26 patients, only two were females. Involvement of left side was seen more than right one. None had bilateral involvement. Adults in the age group of 31-40 were commonly affected. Most common site of involvement was scaphoid and triangular fossa. The success rate with primary I and D and buttoning was 96%. **Conclusions:** Pseudocyst of the pinna is a benign condition of unknown etiology affecting the pinna, commonly encountered in middle-aged men. Many modalities of treatment have been recommended in the literature with varied recurrence and failure rates. The best form of treatment with minimum recurrence is incision and drainage with removal of anterior cartilage leaflet with buttoning.

Key words: Buttoning, pinna, pseudocyst, surgical deroofing

differential diagnosis of this condition includes cellulitis, relapsing polychondritis, chondrodermatitis helices, and subperichondrial hematoma secondary to trauma.^[2] The ideal treatment is the preservation of the anatomical architecture of the pinna and prevention of recurrence. The treatment of this condition varies widely in the literature. Most accomplished results were obtained by incisional drainage, followed by chemical and mechanical obliteration such as pressure dressing with button bolsters and compression suture therapy. Chemical obliteration is performed by intracartilaginous trichloroacetic acid and intralesional corticosteroid. Resection of the anterior cartilaginous leaflet of the pseudocysts with repositioning of the overlying skin flap or the so-called *deroofing technique* followed by buttoning is seen to produce best results in the literature.^[4]

Access this article online

Quick Response Code:



Website:

www.jstcr.org

DOI:

10.4103/2006-8808.128728

Address for correspondence: Dr. Nazir A. Khan,
Department of ENT and HNS, SKIMS Medical College,
Srinagar, Jammu and Kashmir, India.
E-mail: Skims.nkhan@gmail.com

We present our experience of 26 patients of pseudocyst of auricle diagnosed in our medical colleges from April 2011 to April 2013 in terms of clinical features and its management with surgical deroofing and buttoning.

MATERIALS AND METHODS

This prospective study was done in the Department of ENT and Head and Neck Surgery, of SKIMS Medical College, Srinagar and Government Medical College, Srinagar.

Twenty-six patients with pseudocysts of the pinna were enrolled in the study for a period of 2 years from April 2011 to April 2013 after they understood and accepted the procedure.

Pseudocysts were diagnosed on the basis of clinical presentation, characteristics of the aspirated fluids, no evidence of infection, and absent signs of inflammation.

All patients irrespective of the size of pseudocyst underwent incision and drainage with removal of anterior leaflet of cartilage followed by buttoning for 12 days.

Procedure

Pinna was cleaned with Savlon and Betadine and draped. About 0.1-0.2 mL of fluid was aspirated from all groups by a 1-mL syringe which was physically inspected and sent for culture. Xylocaine with adrenaline is infiltrated locally. An incision was given superiorly over the swelling, and the skin was elevated beyond the margin of the cyst [Figure 1]. The anterior lining of the cyst was removed in piecemeal. The posterior cartilage lining of the cyst wall was usually left intact. When the swelling was seen to extend to posterior aspect of pinna, we removed a small window cartilage posteriorly.

The incision was closed with 5-0 prolene, and buttons of appropriate site were applied on the anterior and posterior aspect and tied with through and through 4-0 silk sutures [Figures 2 and 3]. No external bandage was applied.

Anti-inflammatory and antibiotics drugs were prescribed for 5 days, and the buttons were removed after 12 days. Rebuttoning was done in cases who failed primary buttoning after a gap of 1 month.

Patients were followed for 2 months after completion of successful treatment.

RESULTS

Total number of patients enrolled in the study were 26 and only two were females. Maximum numbers (i.e. 11) of patients were in the age group of 31-40 comprising about 42% of study population [Table 1]. Maximum number (i.e. 10) of patients had swelling involving predominantly triangular, scaphoid, and antihelix [Figure 4] followed by triangular fossa (5) [Figure 5] while minimum number (3) involved concha [Figure 6 and Table 2].

Culture of the aspirated fluid from pseudocyst was sterile in all cases.

The maximum number (10) of patients were laborers by profession while government employees comprised the minimum number [Table 3]. Involvement of both right and left ears was seen, but left ear was involved more than right with 16 and 10 cases, respectively. None of the cases had bilateral pseudocyst. The fluid aspirated was straw serum colored in majority of patients (15) while few of them (2) had serosanguinous fluid. The volume of the fluid ranged from 1 to 4 mL. The size of the swelling ranged from 1.5 to 4.5 cm in largest diameter [Table 4].

Reaccumulation of fluid was seen in only one patient after primary incision and drainage and buttoning [Table 5]. The

Table 1: Age and sex distribution of patients

Age group in years	Male	Female	Total
<10			
11-20	2		2
21-30	4	1	5
31-40	10	1	11
41-50	6		6
51-60	2		2

Table 2: Sites of involvement

Sites	Number of cases
Triangular fossa+scaphoid fossa+antihelix	10
Concha	3
Triangular fossa	5
Scaphoid fossa	4
Diffuse swelling	4
Total number of patients	26

Table 3: Profession of patients

Profession	Number of patients
Labor class	10
Business class	9
Government service	3
Student	4

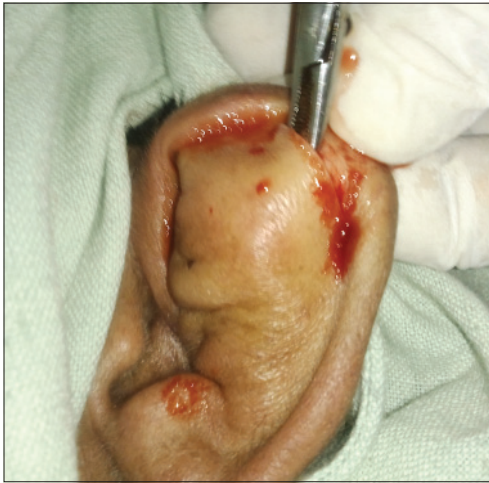

Figure 1: Incision over the pseudocyst

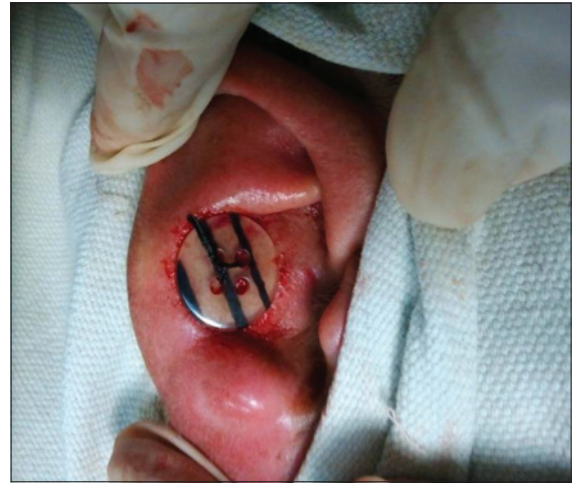

Figure 2: Buttons tied to pseudocyst

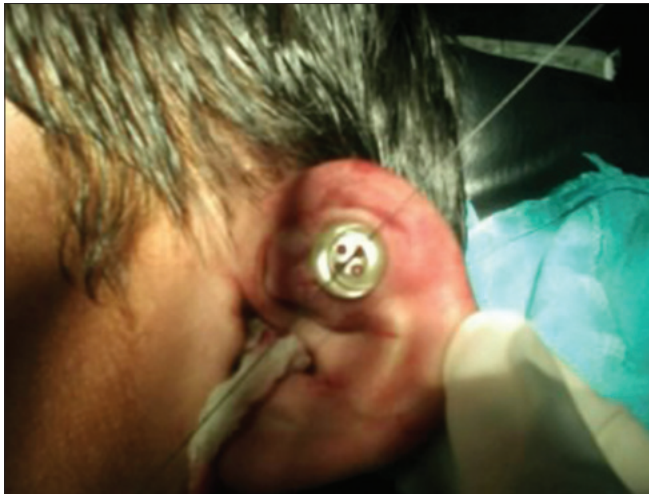

Figure 3: Buttons being tied to pseudocyst

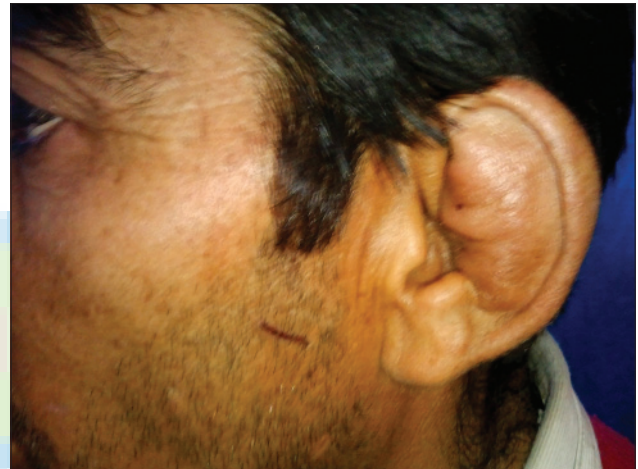

Figure 4: Pseudocyst involving antihelix, triangular fossa, and scaphoid fossa

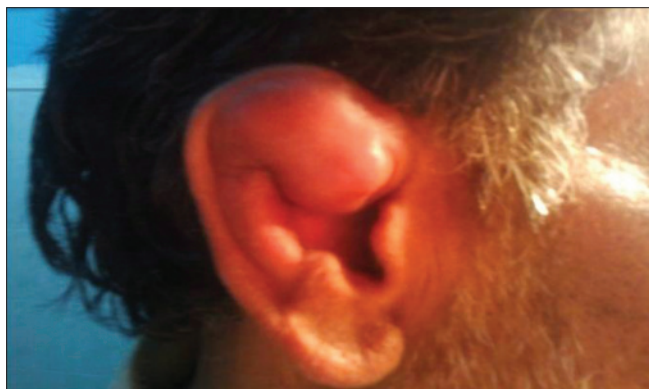

Figure 5: Pseudocyst predominantly involving triangular fossa

success rate was 96% in primary cases. One patient that failed primary I and D and buttoning underwent incision and drainage with removal of anterior cartilage leaflet and buttoning as a secondary procedure after a month's gap and there was no recurrence after this procedure [Table 6].

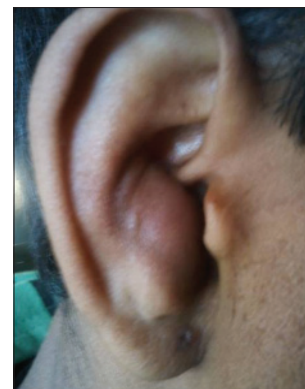


Figure 6: Pseudocyst predominantly involving concha

This procedure was associated with some minor complications. Pain and inflammation of the auricle developed in three patients during the postoperative period that responded promptly to a course of antibiotics and analgesics. In two cases, a mild thickening of the auricle

Table 4: Characteristics of pseudocyst pinna

Characteristics	Number of patients
Color of fluid	
Serosanguinous	2
Straw serum	15
Yellow	9
Size of the swelling (in cm)	1.5-4
Volume of fluid (range in mL)	1-4
Laterality	
Right	10
Left	16
Unilateral	26
Bilateral	X
Duration of existence (range in days)	7-28

Table 5: Findings/complications after 10 days of completion of treatment

Complications	Number of patients
Reaccumulation of fluid (recurrence)	1
Redness/tenderness/erythema of pinna	3
Thickening of the pinna	2
Deformity of the pinna	0

Table 6: Surgical outcome with deroofing and buttoning

Procedure	Number of cases primarily done	Number of recurrent/persistent cases	Number of recurrent cases after buttoning as a secondary procedure
I and D with buttoning	26	1	x

at the site of incision was noticed which persisted. No cauliflower ear developed in patients [Table 5].

DISCUSSION

The first report of pseudocyst of pinna was by Hartmann,^[5] who described 12 cases of intracartilaginous cyst-like swelling of the pinna. Hansen^[6] reported a similar series of six cases in otherwise healthy Caucasian males and labelled them as intracartilaginous cysts but agreed that the term pseudocyst is more appropriate.

Pseudocysts of the auricle occurs more commonly in Chinese and White men.^[1] Although our cases were not histologically confirmed, they shared all the characteristics of pseudocysts. We found pseudocysts predominately in males and only two cases were seen in females. Engel^[1] and Hansen^[6] found them only in males. Lim *et al.*^[7] reported the incidence as 87% in males. A review by Cohen and Grossman^[8] stated that pseudocysts occurred predominantly in men. Shanmugham^[9] and Ramadass and Ayyaswamy^[12] reported two cases in females.

Young children are rarely affected as seen in our study

and in other studies.^[3] However, four children (two boys and two girls) with severe atopic eczema were reported to have the auricular pseudocysts at between 5 and 6 years of age.^[10]

Majority of the pseudocysts were involving scaphoid fossa, triangular fossa, and antihelix followed by concha. Engel^[1] and Cohen and Grossman^[8] also cited the scaphoid fossa and triangular fossa of the antihelix as the main sites of predilection while Supiyaphun and Decha^[3] in contrast noted concha as the most common site of predilection. Pseudocysts usually present unilaterally, but there are reports of bilateral presentation.^[8] Pseudocysts occur more commonly on the right side as reported by many authors^[8] but we found them more on the left side. Similar to our study, one study noted pseudocyst to occur more commonly on the left side.^[3] We did not find any bilateral involvement, but the fact is that bilateral lesions are found in only 13% of the patients and are mainly reported in the pediatric age group.^[3]

Typically the straw-yellow viscous fluid similar to olive oil is seen in the pseudocysts; however, serosanguineous and serous fluid may sometimes be observed.^[8] The volume of the aspirates was reported to have a range between 0.5 and 10 mL^[6,8] and we found it between 1 and 4 mL. Typically, the swelling develops in 4-12 weeks.^[2] The size ranged from 1 to 5 cm in diameter^[2] and we found it between 1.5 and 4.5 cm.

Histologically, pseudocyst is characterized by an intracartilaginous cavity lacking in epithelial lining (hence named pseudocyst),^[11] and contain thinned cartilage and hyalinising degeneration along the internal border of the cystic space and granulation tissue.^[2]

The maximum number of patients in our study were laborers by profession followed by businessmen while government employees comprised the minimum number. Although we did not statistically analyzed trauma as a cause of pseudocyst pinna but we are of opinion that trauma to ear as such is more likely to be seen in laborers and businessmen because of the nature of work they do.

The ultimate aim of treatment is successful drainage of the pseudocyst without damage to healthy cartilage and to prevent its recurrence. The treatment of this condition varies in the literature because of the inherent recurrence.

Different forms of treatment have been described in several case reports and small series to overcome the

recurrence: Simple observation for 3 months;^[12] simple aspiration followed by pressure dressing applied on the pinna for 2 weeks;^[2] aspiration of fluid followed by injection of various substances such as steroids, 50% trichloroacetic acid, and triamcinolone;^[13] oral corticosteroids alone;^[13] incision and drainage with curettage and pressure dressing;^[13] needle aspiration plus bolstered pressure sutures applied over both aspects of the cyst;^[3] surgical curettage and fibrin sealant has been shown to be effective in obliterating the cystic cavity;^[13] treatment by incisional biopsy;^[4] resection of the anterior cartilaginous leaflet of the pseudocysts with repositioning of the overlying skin flap or the so-called deroofting technique followed by buttoning.^[14] Simple punch biopsy followed by the application of a bolster for approximately 2 weeks;^[15] CU-VAC technique;^[3] drainage tube inserted into the pseudocyst using a guide needle;^[16] a piece of cartilage removed posteriorly and corrugated drain kept in place;^[17] intralesional injections of minocycline hydrochloride (1 mg/mL) two to three times at 2-week intervals have shown efficacy.^[18]

The most effective technique for pseudocyst is incision and drainage with removal of anterior leaflet of cartilage with approximation of skin followed by buttoning the so-called *surgical deroofting technique*. The success rate in our study with this procedure was 96% and recurrence was seen in only one patient. This procedure has been found to be the best approach in many studies. Lim *et al.* in their series found that none of the patients had recurrence following excision and compression buttoning of the pseudocyst. Choi *et al.*^[11] performed this procedure and the majority of cases they treated by this procedure was successful. Harder and Zachary^[19] in their series found a normal-appearing auricle with minimal scarring or recurrence. Chang *et al.*^[20] and Kanotra and Lateef.^[14] found no recurrence after removing anterior leaflet of the pseudocyst. Tan^[21] found recurrence in only 2.5% after surgery. Hoffman *et al.*^[22] and Mohammed and Jakubikova^[23] successfully treated patients with this technique. A previous study in our department by Patigaroo *et al.*^[12] found no recurrence with surgical deroofting and buttoning. Although this procedure is the best, it is associated with minor complications as seen in our study. Perichondrial reaction and thickening of pinna were the common complications which we noticed. Perichondrial reaction subsided with antibiotics and anti-inflammatory drugs. We did not see any patient with Frank perichondritis, the most dreaded complication expected due to the exposure of the perichondrium because we took all possible care to do incision and drainage under aseptic conditions. Proper surgical

and postoperative care of the wound can minimize if not prevent most of the complications and hence this procedure can be recommended for treating auricular pseudocysts.

CONCLUSION

Pseudocyst of the pinna is a painless benign condition commonly encountered in middle-aged persons. It occurs commonly, unilaterally, and in males. Despite its unclear etiology, chronic low-grade trauma is one of the etiological factors in its development. Many modalities of treatment have been recommended in the literature with varied recurrence and failure rates. Considering the rate of success, we would like to advocate incision and drainage with removal of anterior cartilage leaflet and buttoning (deroofting procedure) as being the best method that can be undertaken in the management of auricular pseudocysts.


REFERENCES

- Engel D. Pseudocyst of the auricle in Chinese. *Arch Otolaryngol* 1966;83:197-202.
- Ramadass T, Ayyaswamy G. Pseudocyst of auricle etiopathogenesis, treatment update and literature review. *Indian J Otolaryngol Head Neck Surg* 2006;58:156-9.
- Supiyaphun P, Decha W. Auricular pseudocysts: A treatment with the Chulalongkorn University vacuum device. *Otolaryngol Head Neck Surg* 2001;124:213-6.
- Lee YK, Ku BS, Kim YH. A case of pseudocyst of the auricle treated by incisional biopsy. *Korean J Dermatol* 2007;45:518-20.
- Hartmann A. Über Cystenbildung in der Ohrenmuschel. *Arch Ohren Nasen Kehlkopfheilkd* 1846;15:156-66.
- Hansen JE. Pseudocyst of the auricle in Caucasians. *Arch Otolaryngol* 1967;85:1-13.
- Lim CM, Goh YH, Chao SS, Lynce L. Pseudocyst of the auricle. *Laryngoscope* 2002;112:2033-6.
- Cohen PR, Grossman ME. Pseudocyst of the auricle: Case report and world literature review. *Otolaryngol Head Neck Surg* 1990;116:1202-4.
- Shanmugham MS. Pseudocyst of the auricle. *J Laryngol Otol* 1985;99:701-3.
- Devlin J, Harrison CJ, Whitby DJ. Cartilaginous pseudocyst of the external auricle in children with atopic eczema. *Br J Dermatol* 1990;112:699-704.
- Choi S, Lam K, Chan KW, Cohadially FN, Anthony SM. Endochondral pseudocyst of the auricle in Chinese. *Arch Otolaryngol* 1984;110:792-6.
- Patigaroo SA, Mehfooz N, Patigaroo FA, Kirmani MH, Waheed A, Bhat S. Clinical characteristics and comparative study of different modalities of treatment of pseudocyst pinna. *Eur Arch Otorhinolaryngol* 2012;269:1747-54.
- Karabulut H, Acar B, Selcuk K. Treatment of the nontraumatic auricular pseudocyst with aspiration and intralesional steroid injection. *New J Med* 2009;26:117-9.
- Kanotra SP, Lateef M. Pseudocyst of pinna: A recurrence free approach. *Am J Otolaryngol* 2009;30:73-9.
- Hegde R, Bhargava S, Bhargava KB. Pseudocyst of the auricle: A new method of treatment. *J Laryngol Otol* 1996;110:767-9.
- Ramalingam R, Ramalingam KK. Pseudocyst of the auricle: A new method of treatment. *Indian J Otolaryngol Head Neck Surg* 1998;50:172-4.
- Sangeetha RH, Vijayendra H. A safe and reliable technique in the management of pseudocysts. *Indian J Otolaryngol Head Neck Surg* 2004;56:29-30.
- Oyama N, Satoh M, Iwatsuki K, Kaneko F. Treatment of recurrent auricle

- pseudocyst with intralesional injection of minocycline: A report of two cases. *J Am Acad Dermatol* 2001;45:554-6.
19. Harder MK, Zachary CB. Pseudocyst of the ear. Surgical treatment. *J Dermatol Surg Oncol* 1993;19:585-8.
 20. Chang CH, Kuo WR, Lin CH, Wang LF, Ho KY, Tsai KB. Deroofing surgical treatment for pseudocyst of the auricle. *J Otolaryngol* 2004;33:177-80.
 21. Tan BY. Auricular pseudocyst in the tropics: A multi-racial Singapore experience. *J Laryngol Otol* 2004;118:185-8.
 22. Hoffmann TJ, Richardson TF, Jacobs RJ, Torres A. Pseudocyst of the auricle. *J Dermatol Surg Oncol* 1993;19:259-62.
 23. Mohammed E, Jakubikova J. Bilateral pseudocyst of pinna: A case report. *Bratisl Lek Listy* 2007;108:470-3.

How to cite this article: Khan NA, ul Islam M, ur Rehman A, Ahmad S. Pseudocyst of pinna and its treatment with surgical Deroofing: An experience at tertiary hospitals. *J Surg Tech Case Report* 2013;5:72-7.

Source of Support: This study was self financed and our group did not receive any financial support from our institutions, **Conflict of Interest:** None declared.



“Quick Response Code” link for full text articles

The journal issue has a unique new feature for reaching to the journal’s website without typing a single letter. Each article on its first page has a “Quick Response Code”. Using any mobile or other hand-held device with camera and GPRS/other internet source, one can reach to the full text of that particular article on the journal’s website. Start a QR-code reading software (see list of free applications from <http://tinyurl.com/yzlh2tc>) and point the camera to the QR-code printed in the journal. It will automatically take you to the HTML full text of that article. One can also use a desktop or laptop with web camera for similar functionality. See <http://tinyurl.com/2bw7fn3> or <http://tinyurl.com/3ysr3me> for the free applications.