

Mini-screw supported molar distalization: A new method

Ahmet Arif Celebi

Department of Orthodontics, Faculty of Dentistry, Zirve University, Gaziantep, Turkey

ABSTRACT

The aim of this report was to present the results of most effective intraoral upper molar distalization system supported with mini-screw. The mini-screws with a 2.0 mm diameter and 8 mm length were used for intra-osseous anchorage. The screws were placed right and left buccal side of the maxilla. Nickel-titanium (NiTi) coil springs were set bilaterally on a 0.016 inch diameter NiTi archwire between the first molar tubes and the first premolar braces. The first premolars were ligated to the mini-screw to provide anchorage. Other mini-screws with a 2.0 mm diameter and 10 mm length were placed right and left palatal side. A spring consisted of a 0.017 × 0.025 inch beta-titanium-alloy wire situated palatally. The activated wire was inserted among the first molar palatal sheath and the mini-screw. Distalization of the upper molars was achieved in average 5 months. According to the results, the maxillary first molars showed mean 4 mm distal movement and 4° distal tipping.

Key words: Distalization, maxillary molar, mini-screw

Introduction

Treatment of Class II malocclusions, without extractions, usually requires distalization of maxillary molars. Conventional extraoral appliances are usually used for supporting maxillary molar anchorage or for distalization purposes. However, the major disadvantage of an extraoral method is a lack of patient cooperation during treatment.^[1,2] Alternatively, several methods have been introduced for molar distalization in the treatment of dental Class II malocclusions.^[3-8] Intraoral appliances for maxillary molar distalization, such as the pendulum,^[3] push-coils,^[9] magnets,^[10] superelastic nickel-titanium (NiTi) wires,^[11] distal jet,^[12] and molar slider,^[13] do not require extensive cooperation from the patient. Those appliances effectively distalize the maxillary molars; however, in most of these appliances, anchorage loss is unavoidable, characterized by maxillary incisor protrusion, increased overjet, and decreased overbite.^[4,14] Investigators have been directed

to use temporary anchorage devices to overcome this side effect. With the use of dental implants, mini-plates, and mini-screw implants as anchorage, the distal movement of anterior teeth or posterior teeth (or both) without anchorage loss has become possible.^[15,16]

The present prospective study was aimed to investigate the efficiency of a newly designed screw supported maxillary molar distalization appliance.

Diagnosis and Treatment Plan

The patient was a 16-year-old girl with a chief complaint of dental crowding in the upper and lower anterior teeth. She had no significant medical and dental history in terms of orthodontic treatment. Her gingival health was moderate, and the radiographs did not reveal any periodontal problem or other pathology.

The patient's profile was mild convex. Vertical facial proportions were normal, and there were significant asymmetries on the mandibula. The temporomandibular joint evaluation showed no signs of clicks or crepitation, and the facial and masticatory muscles were asymptomatic. She had an angle Class II molar relationship on the right side and a weak Class I molar relationship on the left side. The mandibular midline was 3.0 mm to the right of the facial midline [Figure 1]. The dental cast analysis showed 3 mm of

Access this article online

Quick Response Code:



Website:
www.jorthodr.org

DOI:
10.4103/2321-3825.158138

Address for correspondence: Dr. Ahmet Arif Celebi, Department of Orthodontics, Faculty of Dentistry, Zirve University, Gaziantep, Turkey.
E-mail: ahmetarifcelebi@gmail.com

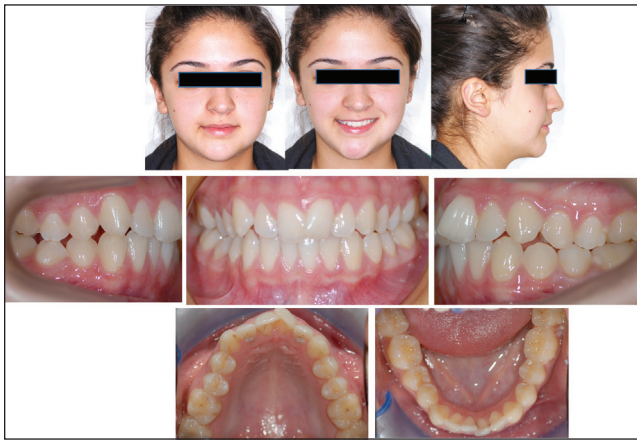

Figure 1: Pretreatment facial and intraoral photographs of the case

space deficiency in the upper arch, 2 mm of space deficiency in the lower arch, 2.5 mm overjet, 1.5 mm overbite, and no Bolton discrepancy. There was no transverse discrepancy.

The initial panoramic radiograph showed no missing teeth, unerupted third molars and alveolar bone and root formation were within normal limits [Figure 2].

The patient had an SNA angle of 80° and SNB angle of 78° , and an ANB angle of 2° . The mandibular plane was high relative to the cranial base (SN-GoGn, 41°). The mandibular incisors had an 87° angle relative to the mandibular plane, and the maxillary incisors had a 107° angle relative to the palatal plane [Table 1].

Treatment Objectives

The treatment objectives, based on the clinical examination and the cephalometric analysis, were to:

1. Relief of crowding.
2. Distalize the maxillary molars to establish a well-intercusated bilateral Class I molar and canine relationship.
3. Correct the midline shift.
4. Create ideal overbite and overjet.

There were four treatment alternatives for this patient:

- (1) Distalization of upper molars using an extraoral traction,
- (2) Distalization of upper molars using an intraoral appliance,
- (3) Extraction of four first premolars, and
- (4) Extraction of maxillary first and mandibular second premolars.

The patient and her parents requested full alignment of the upper anterior teeth, without extractions. There were two choices to achieve this movement: Intraoral distalization mechanics and headgear. The patient refused to wear headgear because of social and esthetic concerns.

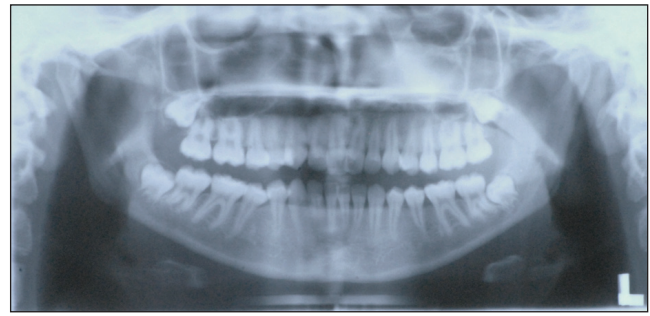

Figure 2: Pretreatment radiographic records of the case

Table 1: Cephalometric measurements of the patient before and after distalization and after orthodontic treatment

Measurements	Before distalization	After distalization	After treatment
SNA	80	79	79
SNB	78	78	78
ANB	2	1	1
Wits (mm)	1	0	0
SN-GoGn	41	42	42
ANS-PNS/GoGn	30	31	31.5
FMA	27.5	28.5	29
U1-NA (mm)	3	5.5	5
U1-NA	21	34	33
U1-ANS-PNS	107	120	118
L1-NB (mm)	4	3.5	3.5
L1-NB	23	30	29
IMPA	87	93	92
U1-PtV (mm)	61	67	67
U6-PtV (mm)	32	28	29
U6/ANS-PNS	80	76	78
Overjet (mm)	2.5	2.5	2.5
Overbite (mm)	1	2.5	2.5
Lower lip-E-line (mm)	-4.5	-3.5	-3.5
Upper lip-E-line (mm)	-7	-5.5	-6
Nasolabial angle	114	112	110

We planned to use intraoral distalizing mechanics combined with mini-screws for distalization of the maxillary first molars.

Treatment Progress

The initial wire placed in the patient immediately after bonding was 0.014-inch NiTi. After 1-month, four mini-screws were used for intra-osseous anchorage. Two mini-screws with a 2.0 mm diameter and 8 mm length were inserted between the first premolar and second premolar on both sides in the maxilla. 0.9 mm in diameter heavy NiTi coil springs were placed bilaterally on a 0.016 inch diameter NiTi archwire between the first molar tube and the first premolar bracket in full compression. The first premolar was ligated to the mini-screw to provide anchorage.

Other two mini-screws with a 2.0 mm diameter and 10 mm length were placed the first and second premolar teeth on the right and left palatal side. A spring consisted of a 0.017 × 0.025 inch beta-titanium-alloy wire situated palatally. An open coil spring compressed between the mini-screw and helix of the wire with cinched back. The activated wire was inserted among the first molar palatal sheath and the mini-screw [Figure 3].

The patient was seen once every month, so the palatally spring pressure and buccally open coil spring pressure checked. If reactivation of palatally spring was needed, it was removed from the lingual sheath. The center of the helix was then held with a bird-beak plier, and the spring was reactivated by pushing it distally toward the midline. It was then reinserted in the sheath.

The maxillary first molars were distalized until a super Class I molar relationship was achieved. The mini-screws, open coils, and titanium–molybdenum alloy wires were removed at the end of distalization, and the maxillary first molars were stabilized by a transpalatal arch. The maxillary second premolars drifted distally without any orthodontic force with the help of the transseptal fibers. After leveling and alignment, a power chain was applied to move the premolars distally. At the end of active treatment, finishing procedures were used for final alignment of the teeth and detailing of the occlusion. The orthodontic appliances were removed after active treatment was completed, and an essix appliance was used for orthodontic retention during a 1-year retention period [Figure 4], finally, a 3-3 maxillary and mandibular fixed lingual retainer were constructed for the patient and then placed.

Treatment Results

The first molar was successfully distalized into an over corrected Class I relationship. After a distalization period of 5 months, the maxillary first molar moved 4 mm distally without anterior movement of the anchor premolars, and the distal tipping of the maxillary first molars was 4°. According to the analysis of the posttreatment lateral cephalometric radiograph, there were increases in overbite (1.5 mm), U1-NA (2 mm), U1-NA(12°), U1-PtV (6 mm), U1-ANS-PNS (11°), L1-NB (6°), IMPA (5°), and decrease in SNA and ANB (1°), Wits (1 mm), U6-PtV (3 mm), U6/ANS-PNS (2°), upper and lower lip-E line (1 mm) [Table 1]. The posttreatment vertical skeletal relationships showed minimal changes in the growth pattern. Root parallelism was confirmed on the posttreatment panoramic radiograph [Figure 5]

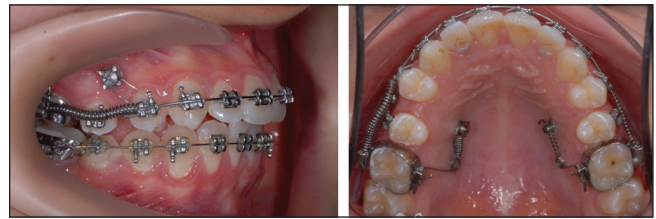


Figure 3: Intraoral buccal and occlusal views of the mechanics

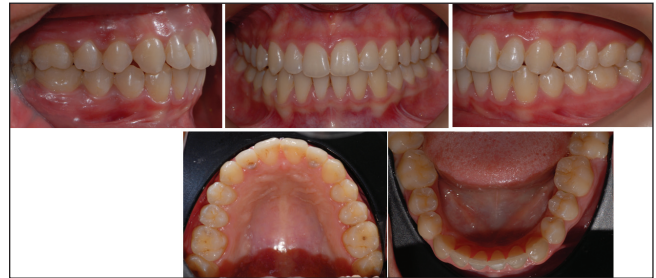

Figure 4: Posttreatment intraoral photographs of the case

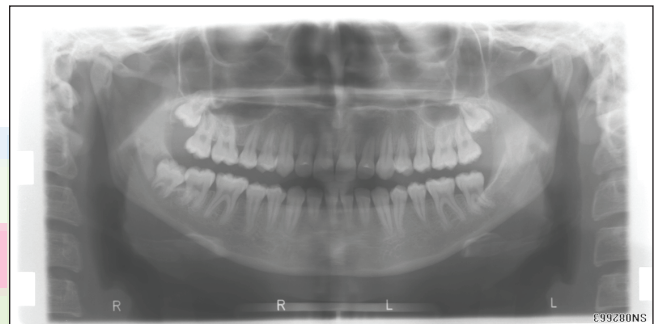

Figure 5: Posttreatment radiographic records of the case

At the end of the 2 years retention period, Class I molar and canine relationships were established with satisfactory interdigitation of the posterior teeth [Figure 6]. Acceptable overjet and overbite were also achieved. The superimpositions of the patient's cephalometric films were done [Figure 7].

Discussion

Several appliances on intraoral maxillary molar distalization without patient cooperation were carried out to overcome the patient compliance problem created by extraoral distalization appliances. These appliances derive their anchorage in an intramaxillary manner and act only in the maxillary arch to move molars distally: Example, the pendulum appliance,^[3] the sectional jig assembly,^[7] the distal jet,^[12] or the first class appliance.^[8] Although there are many intraoral appliances available to move molars distally, none can control molar movement in all three directions.^[17]

The results of this appliance were very satisfactory in that the molars were moved distally and a Class I relationship

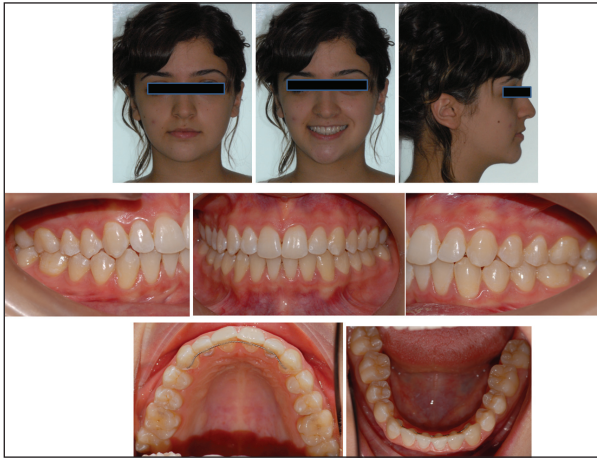

Figure 6: At the end of the 2 years, retention period facial and intraoral photographs of the case

was achieved in 5 months. However, a significant degree of distal crown tipping of upper molars was observed during distalization, which consequently creates the need for additional time, extra uprighting mechanics, and overcorrection of the molar relationship.

One of the important goals of molar distalization is to obtain bodily tooth movement of the molars with minimal rotation and distal inclination. Therefore, distalization was carried out in two sides of (buccally and palatally) first molar teeth. Distalization methods with two sides are rare in the literature. For example, in a study, a combination of two intraoral appliances (the pendulum and the K-loop appliance) was used.^[18]

Recently, mini-screws have been used as stationary anchorage for maxillary molar distalization and other orthodontic purposes.^[19,20] The desired immobility of these screws relies on a mechanical locking between the screw and the surrounding bone. The insertion procedure took 5-8 min and needed no mucoperiosteal flap. All the screws showed primary stability and were loaded almost immediately. This is an advantage over implants that require a healing and osseointegration time of at least 3 months.^[21]

In the current case, the correction of the Class II molar relationship was achieved by a 4 mm distal movement of maxillary first molar into a Class I relationship with a slight distal tipping of 4° after 5 months of distalization. Previous studies^[3,4,12] have indicated that the pendulum appliance produces on average greater molar distalization (3.14-6.1 mm) than the distal jet appliance (2.1-3.2 mm). The distal jet produces better bodily movement (1.8-5° of molar distal tipping) than the pendulum (8.4-15.7°) because the distalizing force is directed close to the level

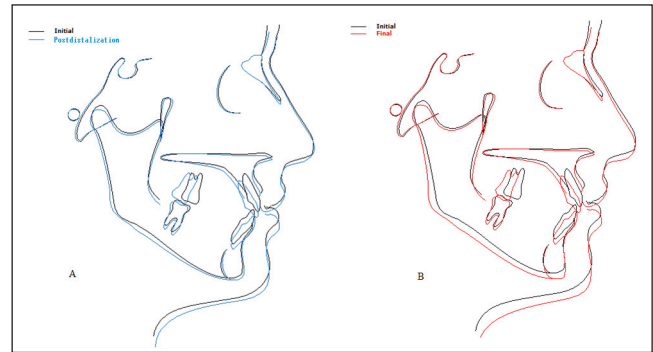


Figure 7: Superimpositions of (a) pretreatment and postdistalization cephalometric tracings and (b) pretreatment and posttreatment cephalometric tracings

of the maxillary first molar's center of resistance. A Jones jig appliance study showed that average distal movement 2.51 mm and distal tipping 7.53° in maxillary first molar at the end of distalization.^[22] The amount of maxillary molar inclination (4° of molar distal tipping) in the present study was smaller than that described in previous studies.

The most interesting advantage of the current system is there is no need for laboratory procedures to manufacture it. Furthermore, the current system can be secured into the lingual sheaths of conventional orthodontic molar bands, with no need for specially designed bands or laboratory procedures to solder tubes or similar attachments on them.

Conclusion

Our treatment results support this new type of treatment biomechanics, since our patient, with a Class II malocclusion, was successfully and efficiently treated to a well-functioning Class I occlusion after 20 months without extractions and without a need for patient cooperation, except for maintaining, as much as possible, optimal oral hygiene.

References

1. Clemmer EJ, Hayes EW. Patient cooperation in wearing orthodontic headgear. *Am J Orthod Dentofacial Orthop* 1979;75:517-24.
2. Egolf RJ, BeGole EA, Upshaw HS. Factors associated with orthodontic patient compliance with intraoral elastic and headgear wear. *Am J Orthod Dentofacial Orthop* 1990;97:336-48.
3. Hilgers JJ. The pendulum appliance for Class II non-compliance therapy. *J Clin Orthod* 1992;26:706-14.
4. Ghosh J, Nanda RS. Evaluation of an intraoral maxillary molar distalization technique. *Am J Orthod Dentofacial Orthop* 1996;110:639-46.
5. Byloff FK, Darendeliler MA. Distal molar movement using the pendulum appliance. Part 1: Clinical and radiological evaluation. *Angle Orthod* 1997;67:249-60.

6. Gulati S, Kharbanda OP, Parkash H. Dental and skeletal changes after intraoral molar distalization with sectional jig assembly. *Am J Orthod Dentofacial Orthop* 1998;114:319-27.
7. Haydar S, Uner O. Comparison of Jones jig molar distalization appliance with extraoral traction. *Am J Orthod Dentofacial Orthop* 2000;117:49-53.
8. Fortini A, Lupoli M, Giuntoli F, Franchi L. Dentoskeletal effects induced by rapid molar distalization with the first class appliance. *Am J Orthod Dentofacial Orthop* 2004;125:697-704.
9. Gianelly AA, Bednar J, Dietz VS. Japanese NiTi coils used to move molars distally. *Am J Orthod Dentofacial Orthop* 1991;99:564-6.
10. Gianelly AA, Vaitas AS, Thomas WM. The use of magnets to move molars distally. *Am J Orthod Dentofacial Orthop* 1989;96:161-7.
11. Locatelli R, Bednar J, Dietz VS, Gianelly AA. Molar distalization with superelastic NiTi wire. *J Clin Orthod* 1992;26:277-9.
12. Carano A, Testa M. The distal jet for upper molar distalization. *J Clin Orthod* 1996;30:374-80.
13. Keles A. Unilateral distalization of a maxillary molar with sliding mechanics: A case report. *J Orthod* 2002;29:97-100.
14. Gelgör IE, Büyükyılmaz T, Karaman AI, Dolanmaz D, Kalayci A. Intraosseous screw-supported upper molar distalization. *Angle Orthod* 2004;74:838-50.
15. Park HS, Kwon OW, Sung JH. Nonextraction treatment of an open bite with microscREW implant anchorage. *Am J Orthod Dentofacial Orthop* 2006;130:391-402.
16. Byloff FK, Kärcher H, Clar E, Stoff F. An implant to eliminate anchorage loss during molar distalization: A case report involving the Graz implant-supported pendulum. *Int J Adult Orthodon Orthognath Surg* 2000;15:129-37.
17. Bondemark L. A comparative analysis of distal maxillary molar movement produced by a new lingual intra-arch Ni-Ti coil appliance and a magnetic appliance. *Eur J Orthod* 2000;22:683-95.
18. Acar AG, Gürsoy S, Dinçer M. Molar distalization with a pendulum appliance K-loop combination. *Eur J Orthod* 2010;32:459-65.
19. Kinzinger GS, Gül den N, Yildizhan F, Diedrich PR. Efficiency of a skeletonized distal jet appliance supported by miniscrew anchorage for noncompliance maxillary molar distalization. *Am J Orthod Dentofacial Orthop* 2009;136:578-86.
20. Kircelli BH, Pektas ZO, Kircelli C. Maxillary molar distalization with a bone-anchored pendulum appliance. *Angle Orthod* 2006;76:650-9.
21. Wehrbein H, Feifel H, Diedrich P. Palatal implant anchorage reinforcement of posterior teeth: A prospective study. *Am J Orthod Dentofacial Orthop* 1999;116:678-86.
22. Brickman CD, Sinha PK, Nanda RS. Evaluation of the Jones jig appliance for distal molar movement. *Am J Orthod Dentofacial Orthop* 2000;118:526-34.

How to cite this article: Celebi AA. Mini-screw supported molar distalization: A new method. *J Orthod Res* 2015;3:199-203.

Source of Support: Nil. **Conflicts of Interest:** None declared.

