

## Shoulder function and pain level after revision of failed reverse shoulder replacement to hemiarthroplasty

Seth C. Gamradt, Jonathan Gelber, Alan L. Zhang

### ABSTRACT

**Background:** The reverse total shoulder replacement has become a popular treatment option for cuff tear arthropathy and other shoulder conditions requiring arthroplasty in the setting of a deficient rotator cuff. Despite a revision rate of as much as 10%, to date, there are few reports of reverse replacement conversion to hemiarthroplasty, and none specifically examining shoulder function.

**Materials and Methods:** Six patients with a reverse replacement that was dislocated, infected or loose were revised an average of 9.2 months after the reverse replacement. Two of the three patients that were dislocated also had a known deep infection. Patients with known infection were treated with explant of the reverse prosthesis and conversion to a preformed antibiotic spacer hemiarthroplasty. In three cases with gross loosening of the glenosphere without infection, treatment was performed with removal of glenosphere only, bone grafting of glenoid with allograft and conversion of humeral stem to hemiarthroplasty. Patients were evaluated with outcome scores and physical examination an average of 26.5 months after removal of the reverse prosthesis.

**Results:** The average range of motion postoperatively was forward elevation 42.5 degrees and external rotation 1.7 degrees. The VAS pain score was 2.42 (range 0–6); simple shoulder test was 3.17 (range 1–5); and ASES score was  $52.1 \pm 8.5$ . There were no reoperations to date, and five patients had anterosuperior escape.

**Conclusions:** Safe removal of a reverse replacement and conversion to hemicement spacer or hemiarthroplasty can provide pain relief in those patients with a dislocated or infected reverse replacement. However, the shoulder will likely have very poor function and anterosuperior escape postoperatively. Further studies are needed to determine the optimal treatment for the failed reverse shoulder replacement.

**Level of Evidence:** Therapeutic Level IV.

**Key words:** Arthroplasty, failed, removal, reverse, shoulder

### INTRODUCTION

The reverse shoulder arthroplasty was approved by the FDA in 2004 and has proven a very effective prosthesis for treatment of cuff tear arthropathy and other shoulder conditions requiring arthroplasty in the setting of a deficient rotator cuff. However, in some series, the overall revision rate

for the reverse shoulder is approximately 10%, with instability and infection being the most common precipitating causes.<sup>[1-3]</sup> Studies have also shown that aseptic loosening may contribute to 7% of failures,<sup>[3]</sup> but as indications expand and long-term follow-up increases, the incidence of aseptic loosening will likely increase. Guery *et al.*<sup>[4]</sup> have further shown that pain increases with longer term follow-up of reverse replacements

Access this article online

Website:

[www.internationalshoulderjournal.org](http://www.internationalshoulderjournal.org)

DOI:

10.4103/0973-6042.96991

Quick Response Code:



Department of Orthopaedic Surgery,  
University of California, Los Angeles,  
CA, USA

Address for correspondence:

Dr. Seth C. Gamradt,  
Orthopaedic Surgery and Sports  
Medicine, David Geffen School of  
Medicine at UCLA, 10833 Leconte Ave,  
CHS 76-139, Los Angeles, CA 90095,  
USA.

E-mail: [sgamradt@mednet.ucla.edu](mailto:sgamradt@mednet.ucla.edu)

(5–10 years). Therefore, in the future, surgeons will be faced with difficult choices when revising the reverse prosthesis, and optimal management of the failed reverse replacement is not known.

When instability or loosening of a reverse prosthesis does occur, retention of the reverse prosthesis can be performed by (1) increasing deltoid tension with additional polyethylene or metallic spacers, (2) increasing constraint with a retentive cup or (3) revision of the humeral or glenoid components.<sup>[5–14]</sup> However, due to poor bone stock, infection or refractory instability, removal of a reverse replacement (explant) or conversion to hemiarthroplasty can be required.<sup>[15,16]</sup> We present a series of failed reverse replacements that were converted back to hemiarthroplasty with either a metallic prosthesis or preformed antibiotic shoulder spacer for infection, instability or glenosphere loosening. To date, there are few reports of reverse replacement conversion to hemiarthroplasty, and none specifically examining the shoulder function in this unique group.<sup>[5,9,17]</sup> We examine a group of patients after conversion of failed or infected reverse shoulder replacement to hemiarthroplasty; the level of function and pain in this group is important for surgeons and patients considering a revision reverse shoulder replacement.

## MATERIALS AND METHODS

From 2008 to 2010, the senior author performed 115 primary and revision shoulder arthroplasty procedures. As part of the shoulder registry (IRB#10-000859), seven patients were identified that had presented to the senior author's clinic with a reverse replacement that was dislocated (3), infected (4) or loose (3). All of the failed reverse replacements in this study were referred from outside hospitals for tertiary care; revision surgery was performed an average of 9.2 months after implantation of the reverse prosthesis. Two of the three patients that were dislocated also had a known deep infection. Patients with known infection were treated with explant of the reverse prosthesis using a slot osteotomy,<sup>[18]</sup> cement extraction with an Oscar device (Orthosonics, Chatham, NJ, USA) and conversion to a preformed antibiotic spacer hemiarthroplasty ( $n = 3$ ) (Exactech, Interspace, Gainesville, FL, USA). This antibiotic spacer was cemented in place with additional antibiotic-loaded cement (tobramycin and vancomycin). In three cases of gross loosening of the glenosphere, there was no evidence of preoperative infection. These patients were treated with removal of glenosphere only, bone grafting of glenoid with allograft including cancellous bone chips and demineralized bone matrix, and retention of the humeral stem by converting it via the manufacturer's guidelines to a hemiarthroplasty ( $n = 4$ ). At the time of reverse removal in this elderly population, the bone stock of the glenoid was cavitory and uncontained, not deemed of sufficient quality to support immediate replacement of a single-stage revision glenosphere. Preoperative computed tomography (CT) was also used in four patients to evaluate the glenoid bone stock, but was not clinically very useful due to metal artifact.

This group of seven patients' status post removal of reverse replacement were contacted for reevaluation with physical exam and outcome scores specifically for this study. One patient who had been converted from a dislocated, infected reverse replacement to preformed antibiotic spacer chose not to participate, but has not had any further surgery. The case details of the remaining six patients who consented for examination and inclusion in this study are contained in Table 1.

## RESULTS

There were three males and three females (average age 74.5 years) who had had an average of three previous shoulder surgeries including the index reverse replacement. Table 1 summarizes the results of this series of patients. The reverse replacement had been implanted an average of 9.2 months before failure of the prosthesis required removal. Radiographic evidence of technical problems with the index reverse arthroplasty surgery was present in five of six cases, with superior implantation of the glenosphere ( $n = 4$ ) being the most common. Average follow-up after removal of reverse replacement was 26.5 months (range 10–41 months). The decision to include patients with less than 2-year follow-up was made to maximize inclusion of patients that have been offered conversion back to reverse replacement.

Shoulder function was very poor postoperatively (average forward elevation of 42.5 degrees and average external rotation near zero), but the pain level was generally low. The VAS pain score was 2.42 (range 0–6). Simple shoulder test score averaged 3.17 (range 1–5). Average postoperative ASES score averaged  $52.1 \pm 8.5$ . SF-12 scores were similar to US averages in the 75 years-plus age group. Anterosuperior escape was present in five patients (VAS instability score averaged 4.7 [range 0–8]). In the sixth patient, there was static radiographic anterior subluxation (case 1). In the four cases where bone graft was used for glenoid deficiency, radiographic follow-up showed good incorporation of graft and reimplantation with a reverse prosthesis seemed feasible, although none of the patients elected to have this performed. Infectious disease consultation was obtained in cases of infection. A Peripherally Inserted Central Catheter (PICC) line was inserted and culture-specific intravenous antibiotics were administered for 6 weeks postoperatively. There were no reoperations and, to date, no patient has accepted an offer to be converted back to a reverse replacement. Figures 1–3 present three cases of removal of failed reverse replacement.

## DISCUSSION

In Farshad and Gerber's review of reverse arthroplasty complications, they state that the optimal management for a failed reverse arthroplasty is not known and that complications that require removal of the prosthesis result in poor shoulder function.<sup>[9]</sup> Once a severe complication in reverse arthroplasty is established, retention of a stable reverse prosthesis is difficult and multiple reoperations are common. Gallo *et al.* reviewed a

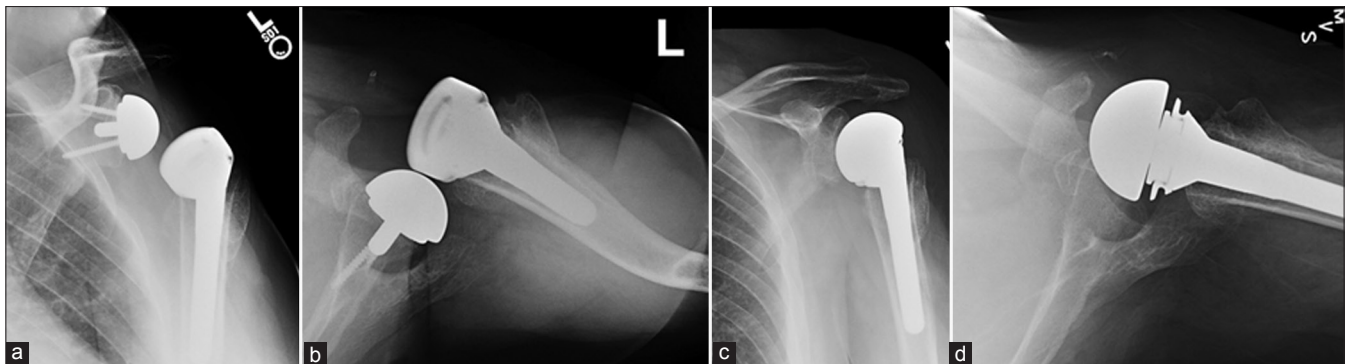
**Table 1: Details of six cases of failed reverse shoulder arthroplasty converted to hemiarthroplasty using either a metallic head and retention of the reverse stem or an explant and implantation of a preformed antibiotic-loaded cement hemiarthroplasty**

Case	Age	Sex	Initial DX	Previous Surgeries of Reverse	Duration of Reverse (months)	Radiographic technical failures	Mode of Reverse Failure	Follow-up (months)	Glenoid Bone Graft	Infection	Current Implant	VAS pain	VAS Instability	Simple Shoulder test	ASES SF12 PCS/MCS	Motion (FE, ER, IR)	AS Escape	
1	81	F	CTA	3	16	None	Infection	10	No	Yes (Strep)	Spacer	3	0	5	48.2	28.9/57.6	60, 10, back pocket	No
2	58	M	FX	2	6	Superior placement of glenosphere	Infection, Anterior Dislocation	18	Yes	Yes (P. Acnes)	Hemi	1	8	1	50	35.8/43.8	20, 20, hip	Yes
3	80	M	CTA	2	15	Superior placement of glenosphere with superior tilt	Loose glenosphere with broken screws	29	Yes	No	Hemi	2.5	3	3	40.8	33.0/56.6	60, 0, hip	Yes
4	74	F	CTA	4	8	Superior placement of glenosphere with superior tilt	Loose glenosphere with broken screws	41	Yes	No	Hemi	6	8	1	46.7	37.5/60.3	30, 0 sacrum	Yes
5	80	M	CTA	4	6	Resection of entire proximal humerus, dislocated in recovery room	Infection, anterior dislocation	28	No	Yes (Peptostrep)	Spacer	0	4	5	65	45.2/63.1	15	Yes
6	74	F	CTA	3	4	Superior placement of glenosphere with superior tilt	Loosening of glenosphere	33	Yes	No	Hemi	2	5	4	61.7	30.3/50.2	70	Yes
AVG	74.5			3	9.2			26.5				2.42	4.67	3.17	52.1	35.1/55.3	42.5, 1.7, NA	
SD												2.06	3.08	1.83	9.32	5.9/7.1		

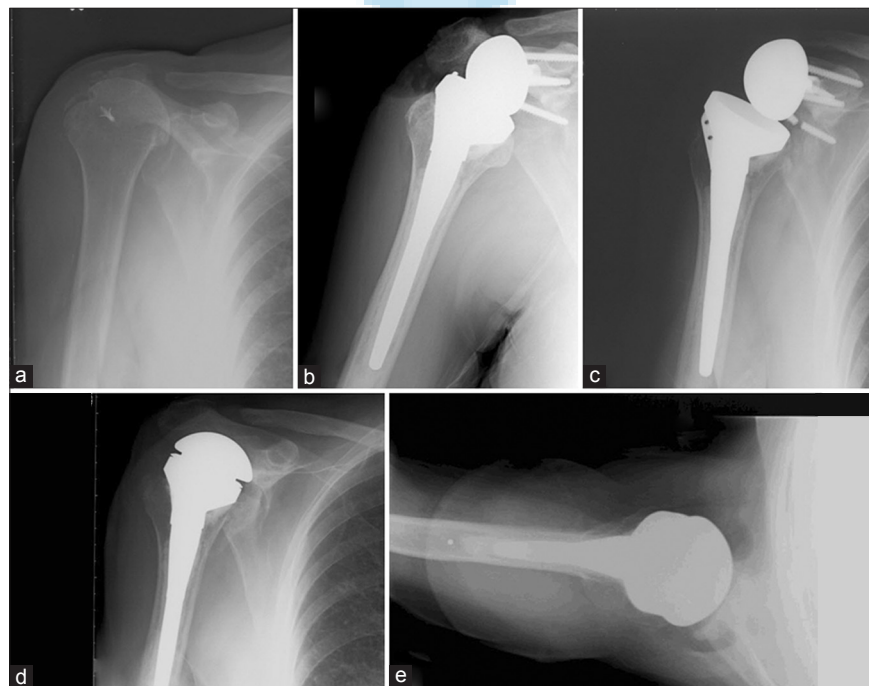
series of nine cases of reverse replacement requiring revision for instability in the setting of subscapularis deficiency.<sup>[15]</sup> In these nine patients, three eventually required explant, three remained chronically dislocated and three were concentrically intact. In a retrospective review of prospectively collected data, Trappey *et al.* describe their experience with dislocation and infection of reverse prosthesis.<sup>[16]</sup> In a series of 284 reverse replacements, the rate of instability was similar in patients with primary (11 of 212 [5%]) and revision (six of 72 [8%]) reverse arthroplasty. The rate of infection was higher in the revision (five of 72 [7%]) than in the primary (three of 212 [1%]) group. In this series, the authors reported that a stable noninfected prosthesis was present in only 12 of 25 shoulders revised for infection or instability, and multiple reoperations for

both persistent infection and recurrent instability were common in this series. In 2008, Norris presented a series of 26 revision reverse replacements for various causes. The reoperation rate was 46.2% and 19.2% of patients required resection arthroplasty.<sup>[20]</sup> Not all series of revision reverse arthroplasty have reported such a high rate of rerevision and reoperation.<sup>[21]</sup>

Comparative data on the optimal treatment for failed reverse replacement is not available.<sup>[19]</sup> If retention of the reverse shoulder prosthesis in the setting of infection, dislocation or loosening is to be performed, the reoperation rate could be as high as 50%, and there is a potential for multiple reoperations and eventual resection arthroplasty. Because of poor bone stock,

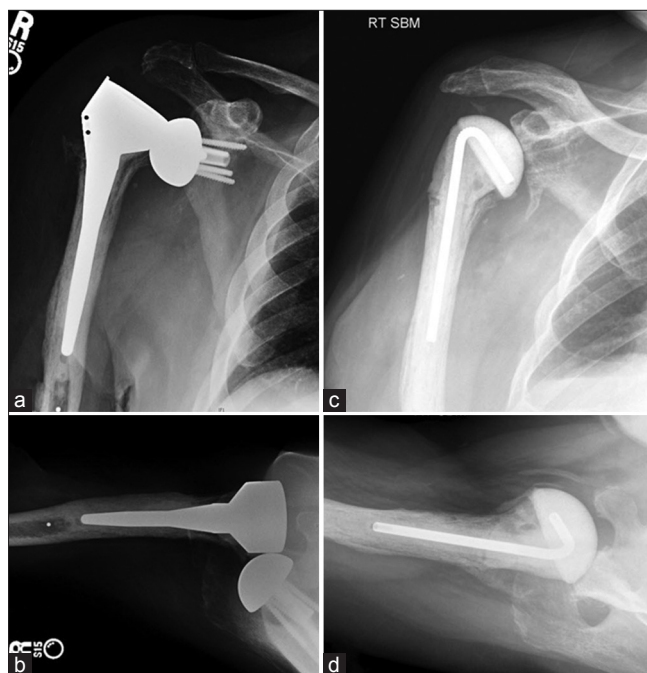

**Figure 1:** A 58-year-old male (Case 2) presented 6 months after reverse arthroplasty for failed fracture fixation with anterior dislocation of the prosthesis. (a and b) Grashey view and axillary view of the dislocated prosthesis. Notice the superior placement of the glenosphere with slight superior tilt. At the time of revision surgery, no combination of glenosphere or reverse humeral component could result in stability as the prosthesis levered out with adduction past 40 degrees. Removal of a well-fixed glenosphere and baseplate was performed and glenoid bone stock was not sufficient for immediate revision of the baseplate to an improved position. (c and d) Conversion to large head hemiarthroplasty and bone grafting of glenoid defect. Cultures were positive for *P. acnes* at the time of revision



**Figure 2:** A 74-year-old female (Case 4) underwent reverse replacement for severe cuff tear arthropathy (a). Immediate postoperative radiographs reveal superior placement of glenosphere (b). The glenosphere loosened at 8 months postoperatively with breakage of the inferior screw (c). (d and e) AP and axillary views after conversion to hemiarthroplasty

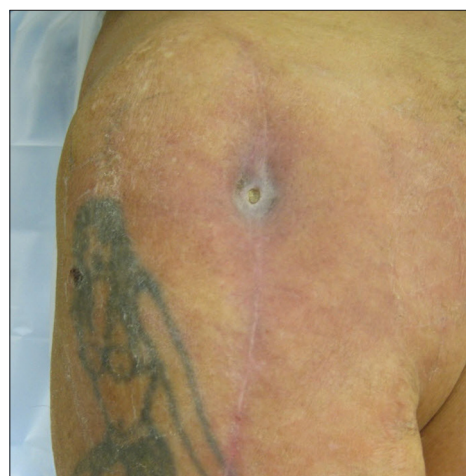



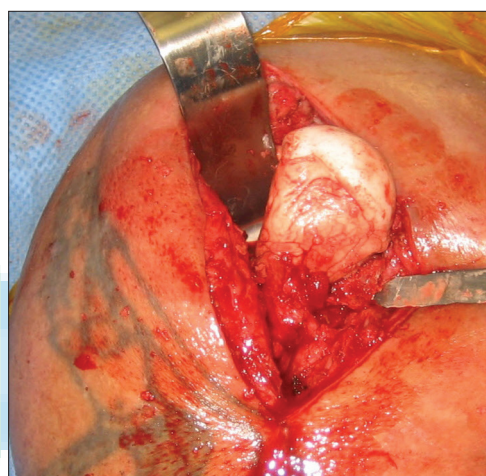
**Figure 3(a-d):** An 80-year-old man (Case 5) presented with a draining sinus and a dislocated, infected reverse replacement 6 months after primary reverse replacement at an outside institution that was complicated with reoperation the same day after a recovery room dislocation. (a and b) Dislocation of reverse replacement. Glenosphere position is acceptable, but the entire humeral head was essentially resected, likely compromising stability. (c and d) Postoperative radiographs of preformed antibiotic spacer

persistent infection or persistent instability, conversion back to reverse replacement is not always possible in the immediate revision setting. In addition, due to the very elderly nature of this population and the often presence of severe medical comorbidities, a surgical strategy that could result in multiple reoperations can be unwise. For this reason, conversion of the reverse replacement to metallic or cement hemiarthroplasty is an attractive option, especially in the multiply operated patient unwilling to harbor further surgical risk. There seems to be less risk of reoperation using this surgical strategy, and the option remains to revise back to reverse replacement at a later date. However, successful single-stage treatment of infected and loose reverse replacements have been reported in the literature.<sup>[8,21,22]</sup>

Few cases have been reported in the reverse arthroplasty literature of conversion to hemiarthroplasty.<sup>[3]</sup> Grammont revised one patient who was revised on postoperative Day 1 due to an intraoperative glenoid fracture, and this patient maintained only 40° of active elevation and had persistent shoulder pain.<sup>[5]</sup> Frankle reported on two patients who were converted to a hemiarthroplasty because of insufficient bone stock and a deep infection; these patients rated the outcome of their revision as good and satisfactory.<sup>[9]</sup> In another large series of reverse replacements, Steinmann reported on a subset of four patients who were converted to a hemiarthroplasty as a result of loosening of the glenoid component in three and recurrent instability in the other. Three of these patients had



**Figure 3e:** Preoperative draining sinus



**Figure 3f:** An intraoperative photograph after irrigation and debridement, removal of glenosphere, slot osteotomy and cementation of preformed antibiotic spacer (Exactech Interspace, Gainesville, FL, USA) with additional antibiotic-loaded cement. Notice how the humeral head is devoid of any soft tissue attachments creating a shoulder with profound anterosuperior escape

moderate pain and one had severe persistent pain, and patient satisfaction was low.<sup>[17]</sup>

This case series can be criticized for the small number of patients included and only very short-term follow-up. While the short-term follow-up may be used to predict future shoulder function, pain has been shown to increase with time.<sup>[4]</sup> Therefore, it is possible that shoulder pain after hemiarthroplasty will become more significant over time, compelling patients to seek further treatment such as reimplantation of a reverse prosthesis. Despite these limitations, the literature is very sparse on “what comes next?” after reverse replacement. We felt that this is the optimal time to report this series as it provides a snapshot of patients that are now candidates for reimplantation of reverse replacement to restore shoulder function. In addition, we feel that this series does provide the shoulder arthroplasty surgeon with several pieces of useful information: (1) in five of six patients, technical error was evident on postoperative radiographs with superior placement

of the glenosphere often with superior tilt accounting for three cases of glenosphere loosening and one case of dislocation. These technical errors likely resulted in the average failure of the index reverse replacement at 9.2 months. (2) In this series, there were no early reoperations. This is important information given the high likelihood of reoperation in revision reverse replacement.<sup>[15,16,20]</sup> The reoperation rate of this series will certainly increase if patients choose to have conversion back to reverse replacement. (3) Pain level was acceptable in most patients after conversion of reverse to hemiarthroplasty, with an average VAS pain score of 2.4. (4) Shoulder function was poor, with anterosuperior escape present in five of six patients. This escape is likely accentuated by reversion to a state where the deltoid is again detensioned.

Failure of reverse replacement will increase in the future, with expansion of indications to younger patients and longer term follow-up. The optimal treatment for a failed reverse replacement is unknown and often very unique to each individual patient and each mode of failure. When counseling a patient with an infected, dislocated or loose reverse replacement, the patient should understand that attempts at retention and salvage of the reverse configuration of their shoulder is not always successful and can be associated with a high rate of reoperation. This small series of patients shows that safe removal of a reverse replacement and conversion to hemicement spacer or hemiarthroplasty can provide the shoulder with a relatively low pain level, but that the shoulder will be nearly devoid of meaningful function postoperatively.

Further studies are needed to compare surgical treatment options for the failed reverse replacement. Every effort should be made to meticulously assure proper initial implant placement and avoid infection in primary reverse replacement. In addition, when complications do occur, retention of the reverse replacement is necessary to maintain shoulder function as conversion to hemiarthroplasty results in poor function. The failed reverse replacement can result in extraordinarily difficult salvage situations and therefore we echo the sentiment published by Rockwood that the reverse replacement should be implanted most frequently by shoulder arthroplasty specialists prepared to treat the severe complications encountered too frequently by even the world's experts.<sup>[23]</sup>

## CONCLUSION


Removal of the reverse shoulder replacement and conversion to hemiarthroplasty results in a shoulder with minimal meaningful function but with an acceptably low level of pain. This information can be helpful when discussing preoperatively the relative risk of revision reverse arthroplasty versus conversion to hemiarthroplasty in patients with a failed reverse replacement.

## REFERENCES

1. Fehring EV, Mikuls TR, Michaud KD, Henderson WG, O'Dell JR. Shoulder arthroplasties have fewer complications than hip or knee arthroplasties in US veterans. *Clin Orthop Relat Res* 2010;468:717-22.
2. Seebauer L. Total reverse shoulder arthroplasty: European lessons and future trends. *Am J Orthop (Belle Mead NJ)* 2007;36:22-8.
3. Zumstein MA, Pinedo M, Old J, Boileau P. Problems, complications, reoperations, and revisions in reverse total shoulder arthroplasty: A systematic review. *J Shoulder Elbow Surg* 2011;20:146-57.
4. Guery J, Favard L, Sirveaux F, Oudet D, Mole D, Walch G. Reverse total shoulder arthroplasty. Survivorship analysis of eighty replacements followed for five to ten years. *J Bone Joint Surg Am* 2006;88:1742-7.
5. Boileau P, Watkinson D, Hatzidakis AM, Hovorka I, Neer Award 2005: The Grammont reverse shoulder prosthesis: Results in cuff tear arthritis, fracture sequelae, and revision arthroplasty. *J Shoulder Elbow Surg* 2006;15:527-40.
6. Boulahia A, Edwards TB, Walch G, Baratta RV. Early results of a reverse design prosthesis in the treatment of arthritis of the shoulder in elderly patients with a large rotator cuff tear. *Orthopedics* 2002;25:129-33.
7. Cuff D, Pupello D, Virani N, Levy J, Frankle M. Reverse shoulder arthroplasty for the treatment of rotator cuff deficiency. *J Bone Joint Surg Am* 2008;90:1244-51.
8. Cuff DJ, Virani NA, Levy J, Frankle MA, Derasari A, Hines B, et al. The treatment of deep shoulder infection and glenohumeral instability with debridement, reverse shoulder arthroplasty and postoperative antibiotics. *J Bone Joint Surg Br* 2008;90:336-42.
9. Frankle M, Siegal S, Pupello D, Saleem A, Mighell M, Vasey M. The Reverse Shoulder Prosthesis for glenohumeral arthritis associated with severe rotator cuff deficiency. A minimum two-year follow-up study of sixty patients. *J Bone Joint Surg Am* 2005;87:1697-705.
10. Levy J, Frankle M, Mighell M, Pupello D. The use of the reverse shoulder prosthesis for the treatment of failed hemiarthroplasty for proximal humeral fracture. *J Bone Joint Surg Am* 2007;89:292-300.
11. Levy JC, Virani N, Pupello D, Frankle M. Use of the reverse shoulder prosthesis for the treatment of failed hemiarthroplasty in patients with glenohumeral arthritis and rotator cuff deficiency. *J Bone Joint Surg Br* 2007;89:189-95.
12. Rittmeister M, Kerschbaumer F. Grammont reverse total shoulder arthroplasty in patients with rheumatoid arthritis and nonreconstructible rotator cuff lesions. *J Shoulder Elbow Surg* 2001;10:17-22.
13. Sirveaux F, Favard L, Oudet D, Huquet D, Walch G, Mole D. Grammont inverted total shoulder arthroplasty in the treatment of glenohumeral osteoarthritis with massive rupture of the cuff. Results of a multicentre study of 80 shoulders. *J Bone Joint Surg Br* 2004;86:388-95.
14. Stine IA, Lee B, Zalavras CG, Hatch G 3<sup>rd</sup>, Itamura JM. Management of chronic shoulder infections utilizing a fixed articulating antibiotic-loaded spacer. *J Shoulder Elbow Surg* 2010;19:739-48.
15. Gallo RA, Gamradt SC, Mattern CJ, Cordasco FA, Craig EV, Dines DM, et al. Instability after reverse total shoulder replacement. *J Shoulder Elbow Surg* 2011;20:584-90.
16. Trappey GJ 4<sup>th</sup>, O'Connor DP, Edwards TB. What Are the Instability and infection rates after reverse shoulder arthroplasty? *Clin Orthop Relat Res* 2011;469:2505-11.
17. Werner CM, Steinmann PA, Gilbert M, Gerber C. Treatment of painful pseudoparesis due to irreparable rotator cuff dysfunction with the Delta III reverse-ball-and-socket total shoulder prosthesis. *J Bone Joint Surg Am* 2005;87:1476-86.
18. Dodson C, Nho S, Codasco F, Craig E, Dines D, Warren R. Anterior humeral window for revision shoulder arthroplasty. *Tech Shoulder Elbow Surg* 2006;7:111-5.
19. Farshad M, Gerber C. Reverse total shoulder arthroplasty-from the most to the least common complication. *Int Orthop* 2010;34:1075-82.
20. Kam G, Norris T, Kelly II J. Early results following revision of reversed total shoulder arthroplasty. In. American Academy of Orthopaedic Surgeons. 75<sup>th</sup> Annual Meeting. San Francisco, CA, USA;2008.
21. Holcomb JO, Cuff D, Petersen SA, Pupello DR, Frankle MA.

- Revision reverse shoulder arthroplasty for glenoid baseplate failure after primary reverse shoulder arthroplasty. *J Shoulder Elbow Surg* 2009;18:717-23.
22. Beekman PD, Katusic D, Berghs BM, Karelse A, De Wilde L. One-stage revision for patients with a chronically infected reverse total shoulder replacement. *J Bone Joint Surg Br* 2010;92:817-22.
  23. Rockwood CA Jr. The reverse total shoulder prosthesis. The new kid on the block. *J Bone Joint Surg Am* 2007;89:233-5.

**Source of Support:** Nil, **Conflict of Interest:** None declared.



### Author Help: Online submission of the manuscripts

Articles can be submitted online from <http://www.journalonweb.com>. For online submission, the articles should be prepared in two files (first page file and article file). Images should be submitted separately.

1) **First Page File:**

Prepare the title page, covering letter, acknowledgement etc. using a word processor program. All information related to your identity should be included here. Use text/rtf/doc/pdf files. Do not zip the files.

2) **Article File:**

The main text of the article, beginning with the Abstract to References (including tables) should be in this file. Do not include any information (such as acknowledgement, your names in page headers etc.) in this file. Use text/rtf/doc/pdf files. Do not zip the files. Limit the file size to 1 MB. Do not incorporate images in the file. If file size is large, graphs can be submitted separately as images, without their being incorporated in the article file. This will reduce the size of the file.

3) **Images:**

Submit good quality color images. Each image should be less than **4 MB** in size. The size of the image can be reduced by decreasing the actual height and width of the images (keep up to about 6 inches and up to about 1800 x 1200 pixels). JPEG is the most suitable file format. The image quality should be good enough to judge the scientific value of the image. For the purpose of printing, always retain a good quality, high resolution image. This high resolution image should be sent to the editorial office at the time of sending a revised article.

4) **Legends:**

Legends for the figures/images should be included at the end of the article file.