

## Sclerosteosis (Truswell-Hansen disease)

S. Deepak Amalnath<sup>1</sup>, M. Vivekanandan<sup>2</sup>

<sup>1,2</sup>Department of Medicine, Indira Gandhi Medical College and Research Institute, Pondicherry, India

Sclerosteosis or Truswell–Hansen disease is a rare autosomal recessive disorder characterized by dense bones, tall stature, and syndactyly. Most of the reports are from South Africa. Here we report the first such case from India.

**Key words:** Sclerosteosis, Truswell–Hansen disease, dense bones, syndactyly

He was born of a consanguineous marriage and the granddaughter of his elder brother was operated for syndactyly [Figure 5]. His family members could not be examined.

### Discussion

### Introduction

Sclerosteosis is a rare autosomal recessive disorder characterized by dense bones, tall stature, and syndactyly. Most of the reports are from South Africa. We report one such pedigree from South India and briefly discuss the genetics of this rare disorder.

### Case Report

A 50-year-old man, diabetic for the past 10 years, presented with poorly controlled diabetes and cataract. Incidentally, he had coarse facial features with frontal bossing and congenital left facial nerve palsy with facial synkinesia [Figure 1]. He also had syndactyly of the left 3<sup>rd</sup> and 4<sup>th</sup> fingers and short right 4<sup>th</sup> finger along with hypoplastic nails [Figure 2]. Radiographs showed dense skull [Figure 3], pelvis [Figure 4], lumbar spine, and fingers. Serum calcium, phosphorus, and alkaline phosphatase were normal.

The clinical picture of dense bones, congenital facial palsy, syndactyly, and an autosomal recessive pattern closely fits the diagnosis of sclerosteosis (Truswell-Hansen disease). Sclerosing bone dysplasias refer to group of bone disorders characterized by dense bones. There are four types of hyperostosis corticalis generalisata.<sup>[1]</sup> Worth disease and Nakamura disease are autosomal dominant disorders characterized by benign course and localized involvement of the facial bones. Van Buchem disease and sclerosteosis are autosomal recessive disorders characterized by generalized bone sclerosis and progressive course.

Sclerosteosis was initially described as osteopetrosis with syndactyly.<sup>[2]</sup>

Van Buchem disease and sclerosteosis are closely related disorders, differentiated by the presence of syndactyly, increased height and rapid progression in the later. Sclerosteosis is of two types. Type 1 is due to mutation of the *SOST* gene coding for sclerostin and has been mapped to 17q12-q21.<sup>[3]</sup> Type 2 is due to mutation of LRP 4 gene<sup>[4]</sup> (low-density lipoprotein receptor-related protein) located at 11p11.2.

Sclerostin is secreted by osteocytes and it down regulates osteoblasts by inhibiting the Wnt pathway mediated b-catenin release. Sclerostin causes the internalization of LRP5; the co receptor of Wnt. LRP4 facilitates the interaction of sclerostin with Wnt. Van Buchem disease is

Access this article online	
Quick Response Code:	Website: www.ijhg.com
	DOI: 10.4103/0971-6866.116109

**Address for correspondence:** Dr. S. Deepak Amalnath, Department of Medicine, Indira Gandhi Medical College and Research Institute, Pondicherry, India. E-mail: drdeepakmddm@yahoo.co.in

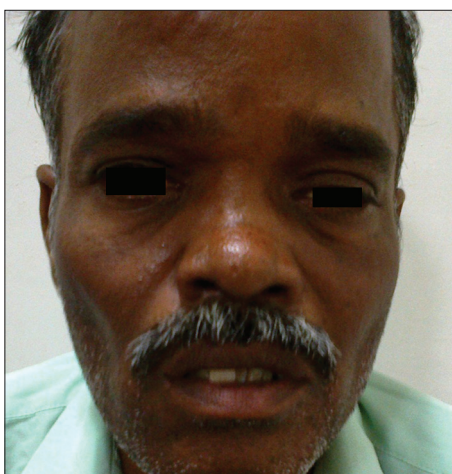


Figure 1: Coarse facial features with left facial palsy

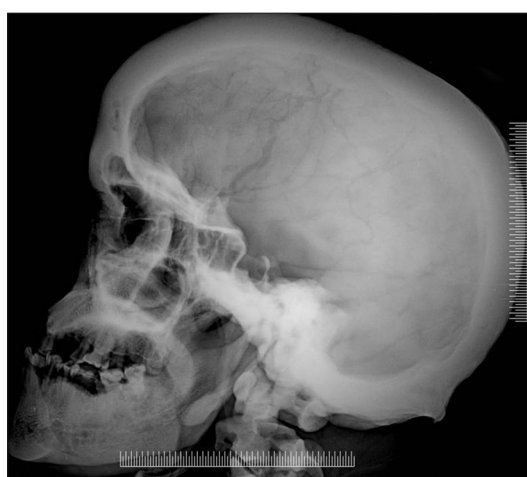

Figure 3: Sclerosed skull bones

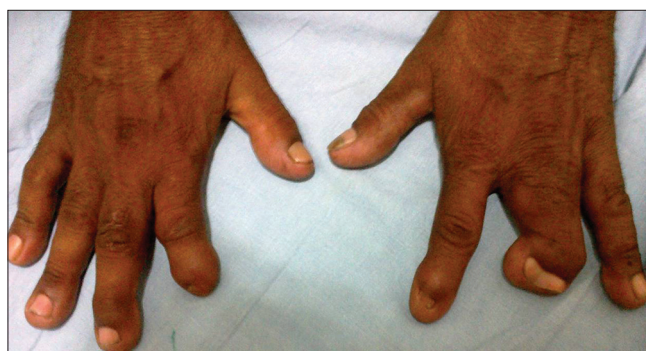

Figure 2: Syndactyly and hypoplastic nails

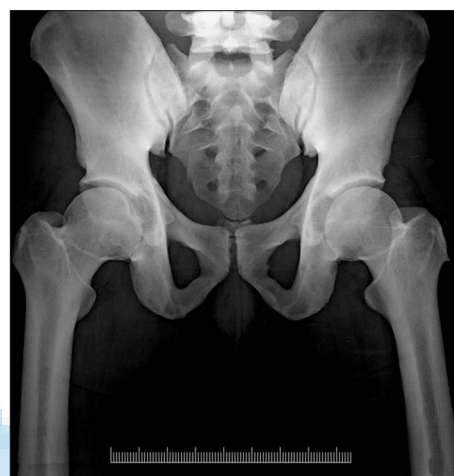

Figure 4: Dense pelvic bones and femorii

Most of the reported patients of sclerosteosis are from the Afrikanar population<sup>[5]</sup> (descendants of the Dutch settlers) of South Africa. To our knowledge, this is the first such report from India.

## Conclusion

Though sclerosteosis is a very rare disorder, the study of its genetics has helped in understanding the various regulators of bone remodeling and may have a therapeutic role in the treatment of osteoporosis and other bone disorders.

## References

1. Ihde LL, Forrester DM, Gottsegen CJ, Masih S, Patel DB, Vachon LA, *et al.* Sclerosing bone dysplasias: Review and differentiation from other causes of osteosclerosis. *Radiographics* 2011;31:1865-82.
2. Truswell AS. Osteopetrosis with syndactyly: A morphological variant of Albers-Schönberg's disease. *J Bone Joint Surg Br* 1958;40-B: 209-18.

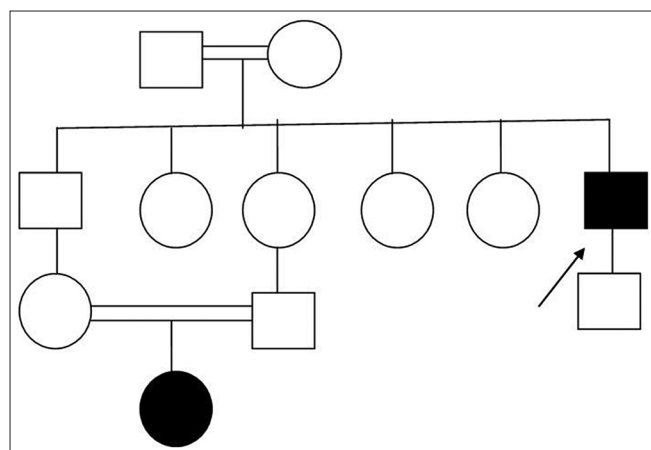


Figure 5: Pedigree chart

also caused by mutations in the downstream regulator of sclerostin. Loss of function of sclerostin leads to increased osteoblastic activity.<sup>[3]</sup> Inhibitors of sclerostin are being tried in the treatment of osteoporosis.

3. Balemans W, Ebeling M, Patel N, Van Hul E, Olson P, Dioszegi M, et al. Increased bone density in sclerosteosis is due to the deficiency of a novel secreted protein (SOST). Hum Mol Genet 2001;10:537-43.
4. Leupin O, Piters E, Halleux C, Hu S, Kramer I, Morvan F, et al. Bone overgrowth-associated mutations in the LRP4 gene impair sclerostin facilitator function. J Biol Chem 2011;286:19489-500.
5. Hamersma H, Gardner J, Beighton P. The natural history of sclerosteosis. Clin Genet 2003;63:192-7.

**Cite this article as:** Amalnath SD, Vivekanandan M. Sclerosteosis (Truswell-Hansen disease). Indian J Hum Genet 2013;19:270-2.

**Source of Support:** Nil, **Conflict of Interest:** None declared.

## FORM IV

*Statement about ownership and other particulars about newspaper (Indian Journal of Human Genetics) to be published in the first issue every year after the last day of February as per Rule 8*

1. Place of publication : Mumbai
  2. Periodicity of its publication : 4 Issues (March, June, September and December)
  3. Printer's Name : Mr. Hemant Manjrekar
  - Nationality : Indian
  - (a) Whether a citizen of India? : Yes
  - (b) If a foreigner, the country of origin : N.A.
  - Address : B9, Kanara Business Center,  
Off Link Rd, Ghatkopar (E),  
Mumbai - 400075, India
  4. Publisher's Name : Mr. Hemant Manjrekar
  - Nationality : Indian
  - (a) Whether a citizen of India? : Yes
  - (b) If a foreigner, the country of origin : N.A.
  - Address : B9, Kanara Business Center,  
Off Link Rd, Ghatkopar (E),  
Mumbai - 400075, India  
Phone: 91-22-6649 1818/1816,
  5. Editor's Name : K. Ghosh
  - Nationality : Indian
  - (a) Whether a citizen of India? : Yes
  - (b) If a foreigner, the country of origin : N.A.
  - Address : National Institute of Immunohaematology (ICMR),  
13<sup>th</sup> Floor, NMS Building, KEM Hospital Campus,  
Parel, Mumbai – 400 012, India
  6. Names and addresses of individuals who own the newspaper and partners or shareholders holding More than one per cent of the total capital. : Indian Society of Human Genetics
- I, **K. Ghosh** hereby declare that the particulars given above are true to the best of my knowledge and belief.

Date: 1<sup>st</sup> August 2013

Mr. Hemant Manjrekar

K. Ghosh