

Mosaic triple X syndrome in a female with primary amenorrhea

A. Venkateshwari, K. Srimanjari, A. Srilekha, Ashrafunnisa Begum, M. Sujatha, T. Sunitha, Pratibha Nallari¹, A. Jyothy

Institute of Genetics and Hospital for Genetic Diseases, Osmania University, Begumpet,
¹Department of Genetics, Osmania University, Hyderabad, India

BACKGROUND: Turner's syndrome is the most common chromosomal abnormality in females, affecting 1 in 2,500 live female births. It is a result of absence of an X chromosome or the presence of a structurally abnormal X chromosome. Its most consistent clinical features are short stature and ovarian failure.

AIM: The aim of the study was to report a rare case of mosaic triple X syndrome in a female with primary amenorrhea.

MATERIALS AND METHODS: The chromosomal analysis using GTG banding was carried out, which revealed a mosaicism with 45,XO/47,XXX chromosomal constitution. Fluorescent *in situ* hybridization was also carried out to further confirm the observation made in the study.

CONCLUSION: The physical features presented by the female could be due to the 45,XO/47,XXX mosaicism and the karyotype analysis was consistent with the diagnosis and clinical symptoms. Triple X mosaicism was confirmed with conventional and molecular cytogenetic analysis.

Key words: Fluorescent *in situ* hybridization, karyotype, primary amenorrhea, Turner's syndrome

the most consistent being gonadal dysgenesis. TS affects approximately 1 in 2,500 live female births, corresponding to approximately 1.5 million women worldwide.^[1]

TS is characterized cytogenetically by X chromosome monosomy, the presence of an abnormal X chromosome, or mosaicism of a 46, XO cell line with another cell line, which might be 46, XX, 46, XY or with an abnormal sex chromosome rearrangement. Pure 45, X monosomy is the most common karyotype and is associated with the most abnormal phenotype.^[2] Mosaicism, represented by 45, XO/46, XX or 45, XO/ 47, XXX cell lineages, has been detected in 30% of TS cases. The severity of clinical manifestation is in part related to the type of chromosomal abnormalities, the time at which chromosome disjunction occurred. and the proportion of compromised cells in each tissue.^[3]

This paper describes and discusses the clinical and cytogenetic findings in a female with a rare sex chromosome abnormality of 45,XO/47,XXX mosaicism.

Introduction

Turner's syndrome (TS) is the result of complete or partial X chromosome monosomy in a phenotypic female, associated with characteristic clinical features,

Case Report

A 24-year-old woman, born to non-consanguineous parents, was referred to our institute for the evaluation of primary amenorrhea. Her birth weight was 3.5 kg, delivered normally, and was the third child in the family. Her developmental milestones were normal. The present weight of the female was 48 kg and height was 154.5 cm. Physical examination showed drooping eyelids and dry eyes. Cubitus valgus was present. Axillary and pubic hair

Access this article online	
Quick Response Code:	Website: www.ijhg.com
	DOI: 10.4103/0971-6866.100790

Address for correspondence: Dr. A. Venkateshwari, Assistant Professor, Institute of Genetics and Hospital for Genetic Diseases, Osmania University, Begumpet, Hyderabad - 500 016, India. E-mail: venkateshwari@yahoo.com

was completely absent indicating androgen insensitivity. Breast development was minimal. Her intelligence quotient was within the normal range. There was no withdrawal bleeding even after taking hormonal pills. There was no history suggestive of such complaints or any other genetic disorders reported in the family. The study was approved by the Institutional Ethical Committee and written consent was obtained from the subject.

Ultrasound scanning of pelvic region showed small uterus with 36 x 7 mm measurement. Endometrium was barely identified as thin echogenic. Ovaries were absent, indicating Mullarian agenesis but the vagina was well visualized.

Hormone profile

Luteinizing hormone (LH: 22.69 mlu/mL) and follicle stimulating hormone (FSH) (64.24 mlu/mL) were in the post-menopausal range (LH: 15.9-54.0 mlu/mL, FSH: 23.0-116.3 mlu/mL) respectively. Serum progesterone (0.05 ng/mL) and prolactin (9.27 ng/mL) levels were also in the post-menopausal range (progesterone: 0.1-0.8 ng/mL, prolactin: 1.8-20.3 ng/mL). Low estradiol concentration (<5.0 pg/mL) was observed and is inconsistent with the diagnosis for primary hypogonadism (<5-54.7 pg/mL). Such a hormonal profile could be due to the ovarian failure.

Cytogenetic evaluation

Cytogenetic analysis was carried out by GTG banding on cultured peripheral blood lymphocytes by

standard technique. Detection of mosaicism depends on the proportion of cells present from the additional cell lineages. In routine karyotyping, 20 cells are counted, since this number is sufficient to detect mosaicism at a level of about 5%.^[4] In the present study, 50 metaphase plates were analyzed in the present study, which revealed mosaicism of 45, XO/47, XXX chromosomal constitution with 65% of the cells showing 45, XO and 35% of the cells exhibiting 47, XXX [Figure 1a and b].

Fluorescent in situ hybridization

Fluorescent *in situ* hybridization (FISH) was carried out using CEP X alpha satellite Vysis probes. Target material on the slide was denatured at 73°C for 5 minutes and then hybridized with ready to use probe mixture for a minimum of 14 h at 37°C. Stringent washing was done to remove unbound probe in 2 X standard saline citrate solution (SSC) at 73°C for 5 min. Preparations were counterstained with 4, 6 diamino 2 phenylindole (DAPI) and visualized using an Olympus fluorescence microscope. Signals were enumerated in 60 interphase nuclei and tested for statistical significance by calculating % coefficient of variance for the signals. FISH analysis confirmed the mosaicism with the presence of two different cell lines, i.e., some of the cells were with three green signals and others with one signal for "X" chromosome [Figure 2].

Discussion

Pure 45, X monosomy is the most common karyotype

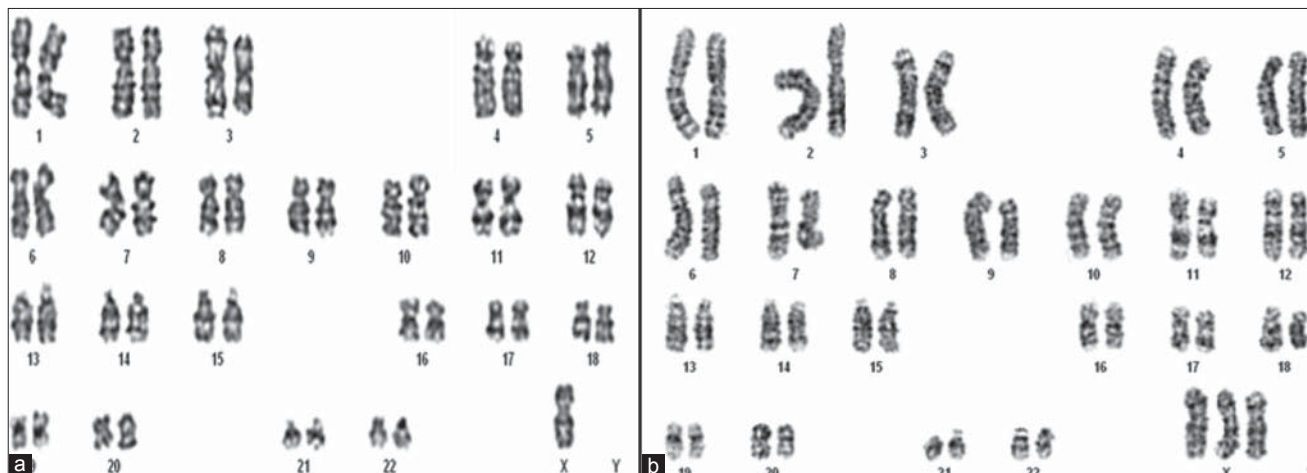


Figure 1: Karyotype of a female with (a) 45, XO and (b) 47, XXX chromosomal constitution

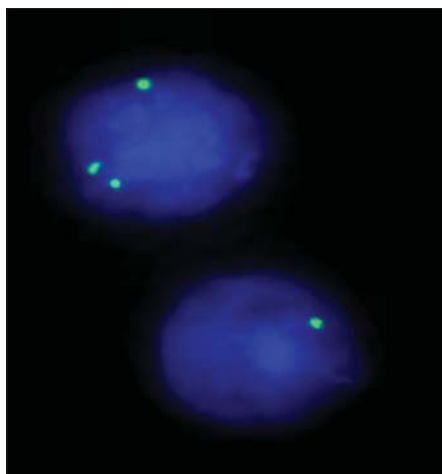


Figure 2: Fluorescent *in situ* hybridization analysis revealed 3 green signals in some cells and one green signal in others, confirming the presence of mosaicism

in TS and is associated with the abnormal phenotype. Some of the phenotypic variability of TS results from the wide variety of karyotypic abnormalities found in affected individuals, ranging from 45, X monosomy to structural defects of the X chromosome to various forms of mosaicism in which two or more cell populations are present, often including a normal 46, XX cell line or an abnormal 47, XXX cell line or both.^[5]

Monosomy X results from nondisjunction as a result of failure of the sex chromatids to separate during meiosis in the parental gamete or in the early embryonic divisions. The latter usually results in mosaicism. Turner mosaics usually have a less severe phenotype and up to 40% enter puberty spontaneously before culminating into gonadal failure.^[2]

Mosaicism, represented by 45, XO/46, XX or 45, XO/47, XXX cell lineages, has been detected in 30% of TS cases. It is generally considered to be the result of nondisjunction in cell division occurring at an early stage in zygotic cleavage. If the error occurs late in cleavage after the establishment of a normal cell line, a multiple cell line mosaic will result.^[4] In the present case, 65% of the cells showed 45, XO chromosomal constitution and the remaining 35% with 47, XXX karyotype.

Short stature is not invariable in this subset of women. Height of the female is normal and is in agreement with the earlier report wherein pure gonadal dysgenesis patients are of normal height and do not show any other stigmata of TS.^[6] The characteristic facies of a female

with TS is also primarily due to skeletal malformations. These result in micrognathia, a downward droop of the outer corner of the eyes and epicanthic folds,^[1] which are prominent in the present study.

The presentation of TS varies at different ages. At any age, TS may be difficult to recognize clinically as the characteristic facial features can be subtle. Patients with a karyotype of 45, XO/46, XX or 45, XO/47, XXX are the most likely to have spontaneous menarche and fertility,^[4] but it was not observed in the present case.

Gonadal dysgenesis is considered a cardinal feature of TS, and the accompanying increase in gonadotropin, especially FSH, secretion has been reported in girls and women with TS.^[5] Elevated levels of LH and FSH in the female are suggestive of ovarian dysfunction. The presence of small uterus could be due to the decreased number of primordial follicles, which appear to undergo premature apoptosis and are usually absent by adult life, and due to lack of estrogen.^[7] Some girls have enough residual ovarian function for breast budding or vaginal spotting to occur.^[8]

Genes related to TS are located in the short arm of the X chromosome, and are able to escape methylation, determining the expression of both alleles.^[9] X chromosome methylation is the most important mechanism to silent the second allele, ensuring adequate gene. Therefore, 45, XO cells develop abnormal parity of sexual chromosomes during meiosis and functioning haploinsufficiency of genes located in the short arm. Several genes related to the clinical signs observed in TS patients have been mapped to this region, including short stature-related genes (Xp11.2-p22.1), ovary function regulatory genes (Xq13-q16), and genes related to lymphatic anomalies (Xp and Yp pseudoautosomal region).^[10] Other than extra X inactivation, the X trisomy cell lineage may produce a failure in the organogenesis of the ovarian tissue, which can be correlated to anestrus and inhibition of germ cells to be meiotic.

In conclusion, the phenotypic characterization of mosaic X chromosome abnormalities depends on the pattern of mosaicism and the nature of aberrant X chromosomes. Thus, it is mandatory to evaluate and offer appropriate counseling to the females with mosaicism and gonadal dysgenesis. Recent advances in the

medical science have enabled a better help to patients with TS, especially in the form of growth hormone and hormone replacement therapy. Timing is also essential when communicating a diagnosis, as it will differ for each patient due to subtle physical variabilities, which will reduce the psychosocial impact of many young girls and women with TS.

Acknowledgement

Authors thankful to Mrs. K. Veena and Mr. N. Panduranga Chary for their technical assistance.

References

1. Elsheikh M, Dunger DB, Conway GS, Wass JA. Turner's syndrome in Adulthood. *Endocr Rev* 2002;23): 120-40.
2. Longui CA, Rocha MN, Martinho LC, Gomes GG, de Miranda RE, Lima TA, *et al.* Molecular detection of XO - Turner syndrome. *Genet Mol Res* 2002;1:266-70.
3. Saenger P, Wikland KA, Conway GS, Davenport M, Gravholt CH, Hintz R, *et al.* Recommendations for the diagnosis and management of Turner syndrome. *J Clin Endocrinol Metab* 2001;86:3061-9.
4. Sybert VP. Phenotypic effects of mosaicism for a 47, XXX cell line in Turner syndrome. *J Med Genet.* 2002;39:217-20.
5. Fechner PY, Davenport ML, Qualy RL, Ross JL, Gunther DF, Eugster EA, *et al.*, on behalf of the Toddler Turner Study Group. Differences in follicle-stimulating hormone secretion between 45,X monosomy Turner syndrome and 45,X/46,XX mosaicism are evident at an early age. *J Clin Endocrinol Metab* 2006;91:4896-902.
6. Seng-Chou Ting, Sheng-Ping Chang. Coexistence of gonadal dysgenesis and mullerian agenesis with two mosaic cell lines 45,X/46,X,del(X) (p22.2). *Zhonghua Yi Xue Za Zhi (Taipei)* 2002;65:450-2.
7. Sybert VP, McCauley E. Turner's syndrome. *N Engl J Med* 2004;351:1227-38.
8. Noor M, Abdullah S, Mahmood S, 2007. Case report. Turner's syndrome. *Gomal J of Med Sci* 2007; 5:133-7.
9. Kosho T, Muroya, K. Nagai, T. Fujimoto, M. Yokoya S, Sakamoto H, *et al.* Skeletal features and growth patterns in 14 patients with haploin sufficiency of SHOX: implications for the development of Turner syndrome. *J Clin Endocrinol Metab* 1999;84:4613-21.
10. Zinn AR, Ross JL. Molecular analysis of genes on Xp controlling Turner syndrome and premature ovarian failure (POF). *Semin Reprod Med* 2001;19:141-6.

Cite this article as: Nallari P, Jyothy A, Venkateshwari A, Srimanjari K, Srilekha A, Begum A, *et al.* Mosaic triple X syndrome in a female with primary amenorrhea. *Indian J Hum Genet* 2012;18:246-9.

Source of Support: Nil, **Conflict of Interest:** None declared.

