

SHORT REPORT

**OPEN ACCESS**  
Full open access to this and  
thousands of other papers at  
<http://www.la-press.com>.

## Exome Sequencing Reveals De Novo Germline Mutation of the Mammalian Target of Rapamycin (MTOR) in a Patient with Megalencephaly and Intractable Seizures

Laurie D. Smith<sup>1,2,4</sup>, Carol J. Saunders<sup>1-5</sup>, Darrell L. Dinwiddie<sup>6,7</sup>, Andrea M. Atherton<sup>1,2,4</sup>, Neil A. Miller<sup>1,2</sup>, Sarah E. Soden<sup>1,2,4</sup>, Emily G. Farrow<sup>1,2</sup>, Ahmed T.G. Abdelmoity<sup>1,2,4</sup> and Stephen F. Kingsmore<sup>1-5</sup>

<sup>1</sup>Center for Pediatric Genomic Medicine, Children's Mercy Hospital, Kansas City, MO, USA. <sup>2</sup>Department of Pediatrics, Children's Mercy Hospital, Kansas City, MO, USA. <sup>3</sup>Department of Pathology, Children's Mercy Hospital, Kansas City, MO, USA. <sup>4</sup>School of Medicine, University of Missouri-Kansas City, Kansas City, MO, USA. <sup>5</sup>University of Kansas Medical Center, Kansas City, KS, USA. <sup>6</sup>Department of Pediatrics, University of New Mexico Health Sciences Center, Albuquerque, New Mexico, USA. <sup>7</sup>Clinical and Translational Science Center, Albuquerque, New Mexico, USA. Corresponding author email: [ldsmith@cmh.edu](mailto:ldsmith@cmh.edu)

---

**Abstract:** A de novo somatic mutation in the mammalian target of rapamycin (*MTOR*) has previously been described in one patient with hemimegalencephaly and epilepsy. Here, we present a case of a young girl with megalencephaly and intractable seizures who was found to have an *MTOR* mutation in multiple cell lineages (p.Cys1483Phe) and, therefore, presumed to be of germline origin. The mutation was detected in peripheral blood DNA by exome sequencing of the patient and her parents, substantiating the utility of this approach for detection of clinically relevant de novo variations.

**Keywords:** Exome, genome, diagnosis, seizure, megalencephaly, de novo mutation, bioinformatics

---

*Journal of Genomes and Exomes* 2013:2 63–72

doi: [10.4137/JGE.S12583](https://doi.org/10.4137/JGE.S12583)

This article is available from <http://www.la-press.com>.

© the author(s), publisher and licensee Libertas Academica Ltd.

This is an open access article published under the Creative Commons CC-BY-NC 3.0 license.



## Introduction

Seizure disorders are common. About 4% of individuals will be diagnosed with epilepsy during their lifetime.<sup>1</sup> Approximately 70% of seizures are currently classified as either idiopathic or cryptogenic, although an underlying genetic etiology might be suspected.<sup>1,2</sup> In the majority of these individuals, the pattern of inheritance is not consistent with a simple, monogenic Mendelian disorder. However, when accompanied by other clinical findings, such as dysmorphic features, the probability of identifying an underlying genetic cause is greater.<sup>1</sup> The advent of exome sequencing technologies has made it possible to evaluate the candidacy of hundreds of potential genetic diagnoses simultaneously in patients with previously molecularly uncharacterized seizure disorders, as well as implicating genes that might not previously have been associated with seizure disorders.<sup>3–5</sup> Furthermore, exome sequencing of an affected patient and unaffected parents (trios), together with bioinformatic tools, has recently made it possible to identify *de novo* mutations that are causative of dominant genetic disorders.<sup>6</sup>

It has long been recognized that dominant mutations in *PTEN* (phosphate and tensin homolog, OMIM 601728), *TSC1* (tuberous sclerosis 1, OMIM 605284), and *TSC2* (tuberous sclerosis 2, OMIM 613254) result in overgrowth syndromes (OMIM 158350, 153480, 191100, 191092) of which seizures are a component. More recently, *de novo* somatic mutations in *MTOR* (mammalian target of rapamycin, OMIM 601231) and germline and postzygotic mutations in *PIK3CA* and *AKT3* (phosphatidylinositol 3-kinase-AKT pathway) have been implicated in hemimegalencephaly (OMIM 605201).<sup>7,8</sup> These gene products are all critical components of the PI3K-AKT3-mTOR pathway. This pathway is a critical intracellular signaling pathway that integrates input from upstream pathways and regulates, among other things, cell growth and proliferation, apoptosis, protein synthesis, and transcription.<sup>9</sup> Furthermore, hyperactivation of this pathway is epileptogenic and associated with neuropathologic abnormalities such as focal cortical dysplasia and hemimegalencephaly.<sup>10</sup> Altered mTOR signaling provides the basis for what are now called “TORopathies,” conditions that are characterized by intractable seizures, focal cortical dysplasia, and hemimegalencephaly.<sup>9,10</sup> The majority of these

conditions (tuberous sclerosis complex (TSC) OMIM 191100, 191092, PTEN hamartoma tumor syndrome 601728) are inherited in an autosomal dominant fashion. As noted above, several have also been found to occur postzygotically and thus result in tissue mosaicism.<sup>7,8</sup> To date, there has only been one clinical report of a mutation in *MTOR* that was identified as a *de novo* somatic event present in affected tissue but not in blood that resulted in hemimegalencephaly and epilepsy.<sup>8</sup> We present the first case of a young girl with megalencephaly and intractable seizures who was found to have a mutation in *MTOR* in multiple cell lineages and, therefore, presumed to be of germline origin. This study also demonstrates the critical role that newer technologies will play in the ability to make medical diagnoses and potentially affect management in rare genetic disorders.

## Case Study

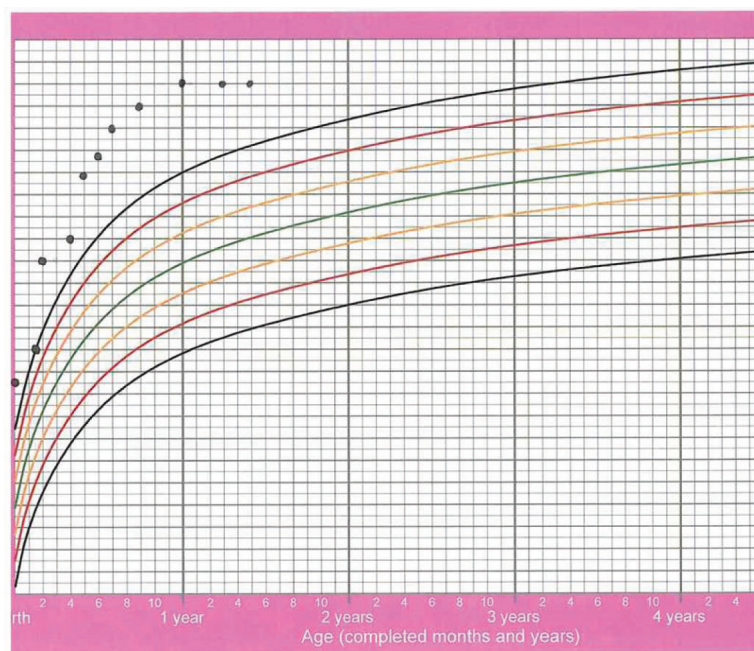
Our patient was a female born at 35 weeks estimated gestational age. She was the product of a second pregnancy to a 26-year-old gravida 2, para 10 mother and 28-year-old father. The pregnancy was complicated by maternal hypothyroidism and prematurity related to preeclampsia diagnosed at estimated gestational age 34 weeks. Fetal movements were described as active, and frequent fetal hiccups were noted. Maternal serum screening and prenatal diagnostic testing were declined. A cesarean section was performed due to frank breech presentation. Birth weight was 2892 grams (84% for gestational age), birth length was 49.5 cm (90% for gestational age), and macrocephaly was noted with an occipitofrontal circumference (OFC) of 39.0 cm (50% for a 2.5 month old). There was some difficulty with delivery secondary to the infant’s large head and supplemental oxygen was required for a short time perinatally. The infant was found to be hypoglycemic and thrombocytopenic. She remained in the neonatal intensive care unit for 19 days due to poor suck and swallow. A brain magnetic resonance imaging (MRI) scan obtained during that hospitalization revealed callosal dysgenesis and mild dilatation of the posterior horns of the lateral ventricles. Expanded newborn screening was normal.

Seizures were first noted during a desaturation event when the infant was admitted to an outside hospital for bronchiolitis. Seizures, described as apnea episodes that were initially not associated with motor

involvement, were noted to be quite frequent, lasting from 10 seconds to 2 minutes. The patient was admitted to our institution at 2 months of age secondary to intractable seizures. The electroencephalogram (EEG) at that time was remarkable for electrographical seizures consisting of a buildup of high voltage (0.5–1.5 Hz) spike and slow wave activity with evolution to faster 2 to 3 Hz spike and slow wave discharges in the left occipito-temporo-parietal region. This was followed by superimposed high voltage 1.5 to 3 Hz focal slowing. There was no clear correlation between clinical findings and EEG changes. The abnormal EEG was felt to be consistent with epileptiform activity along with a focal disturbance in cerebral function over the left occipito-temporo-parietal region. Treatment with antiepileptic medication (oxcarbazepine, and leviteracitam) was attempted but was unsuccessful. The infant was seen by a geneticist for an initial evaluation at that time due to concerns about a possible inborn error of metabolism. She was found to be at the 70th percentile for length and the 21st percentile for weight. Head circumference was found to be at the 50th percentile for a 14 month old (Fig. 1). She had dysmorphic features (Fig. 2), including a large anterior fontanelle, frontal bossing, midface hypoplasia, and a small chin. She was hyperteloritic with downslanting palpebral fissures and a depressed

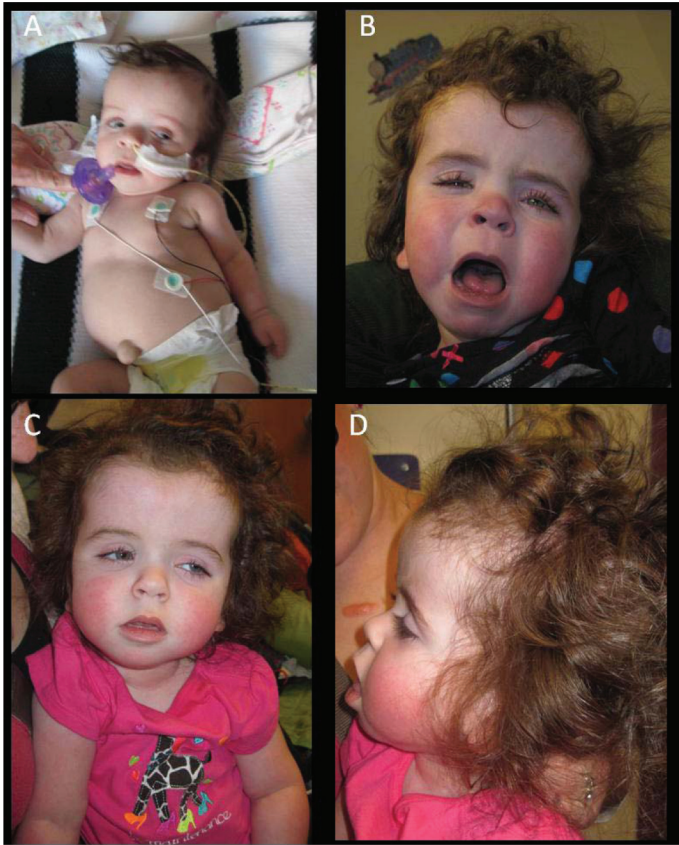nasal bridge. Brows were full and widely spaced. Eyelashes were thick. No cataracts, corneal clouding, or colobomata were identified. Ears were low-set but with otherwise normal architecture. The nose was short and upturned. Philtrum was smooth and the upper lip was thin. The mouth was held slightly open, making the tongue appear prominent. The neck was short without folds or remnants. The thoracic cage appeared narrow. Cardiac and lung exams were normal. There was a sacral cleft but no scoliosis. There was an easily reducible umbilical hernia. There was no organomegaly. External genitalia were normal for age and the anus was nondisplaced. Extremities appeared rhizomelic and hands had a trident appearance with short proximal phalanges. Hips were lax but nondislocatable, and skin folds were asymmetric. There were no unusual markings on the skin. She was mildly hypotonic with poor head control. Deep tendon reflexes were present and symmetric. No unusual movements were noted.

Extensive metabolic and genetic testing was negative. A karyotype and CGH microarray were performed and demonstrated a normal 46, XX karyotype. A skeletal survey was unremarkable, and *FGFR3* gene sequencing was negative, ruling out achondroplasia. A basic metabolic panel was essentially normal as were liver function tests, although indirect bilirubin



**Figure 1.** Occipitofrontal circumference over time (World Health Organization growth chart) demonstrating rapid head growth and macrocephaly.





**Figure 2.** Clinical features of the proband over time. **A.** 3 months of age. **B.** 17 months of age. **C** and **D.** 19 months of age. Note macrocephaly, frontal bossing, prominent forehead, downslanting palpebral fissures, long eyelashes, short upturned nose, umbilical hernia, and myopathic appearance.

was slightly elevated at 1.5 mg/dL (0.0–1.2 mg/dL). Very long chain fatty acids were normal, ruling out Zellweger spectrum disorders. An acylcarnitine profile was also normal consistent with the reported normal state newborn screening results. Mucopolipidosis II/III was ruled out with normal alpha-glucuronidase, alpha-L-fucosidase and beta-hexosaminidase activities. Additionally, a plasma amino acid profile was unremarkable, as were plasma ammonia, plasma lactic acid, and plasma pyruvic acid levels. Notably, there were no elevations of glutamine, alanine, or glycine, and the lactic to pyruvic acid ratio was 12.2 (normal < 20), making a mitochondrial disorder unlikely.

The child was discharged and followed closely in genetics and neurology clinics. While her length and weight remained on the normal growth curves for age, she had rapid growth of her head with head circumferences consistently above the 95th percentile for age (Fig. 2). A repeat EEG at 8 months of age revealed worsening of seizures with multifocal spike, sharp

and slow waves involving both cerebral hemispheres along with signs of severe epileptic encephalopathy. At age 13 months, while on polytherapy with anti-seizure medication (leviteracetam, zonisamide, phenobarbital, and lacosamide), the ketogenic diet with a 3.5:1 ratio was initiated resulting in a decrease in frequency of seizure activity from 4 to 5 seizures per week to 1 less intense seizure per week that lasted anywhere from 20 seconds to 3 minutes. At this time, *PTEN* sequencing was ordered and was negative. Given the negative workup and parental desire to limit venous blood draws, consents were obtained for the patient and her parents to be enrolled in an institutional review board (IRB)-reviewed exome sequencing study at Children's Mercy Hospital, Kansas City, MO. She contracted respiratory syncytial virus pneumonia at 19 months of age and expired secondary to hypoxic respiratory failure.

## Methods

### Consent

The study was approved by the Institutional Review Board (IRB) of Children's Mercy Hospital (CMH). Informed written consent was obtained from both parents.

### Clinicopathologic correlation and interpretation

The features of the patient's disease were mapped to likely candidate genes with SSAGA (Symptom and Sign Assisted Genome Analysis).<sup>5</sup> The symptoms of macrocephaly and epilepsy nominated 44 and 174 genes, respectively (Supplement Table 1). A total of 198 genes were nominated for initial genetic analysis, 20 of which were nominated by both symptoms. Blood samples were obtained from the affected patient and her parents.

### Genome and targeted exome sequencing

DNA isolated from peripheral blood cells was prepared for exome enrichment and next generation sequencing. Briefly, indexed Illumina sequencing libraries were created using the KAPA Biosystems library preparation kit (KAPA Biosystems, Woburn, MA) following manufacturers recommended protocols and 8 cycles of PCR amplification. Exome enrichment was conducted with the Illumina TruSeq



Exome v1 kit, which targets 62.2 megabases, 20,794 genes, and 201,121 exons, following manufacturers protocols (Illumina, San Diego, CA).<sup>11</sup> Successful enrichment was verified by qPCR of 4 targeted loci and 2 non targeted loci of the sequencing library pre- and post-enrichment prior to sequencing. Quantitation of enriched sequencing libraries was assessed by real-time PCR.<sup>11</sup> Samples were sequenced with  $2 \times 100$  base pair sequencing on an Illumina HiSeq 2000 instrument with TruSeq v3 reagents.

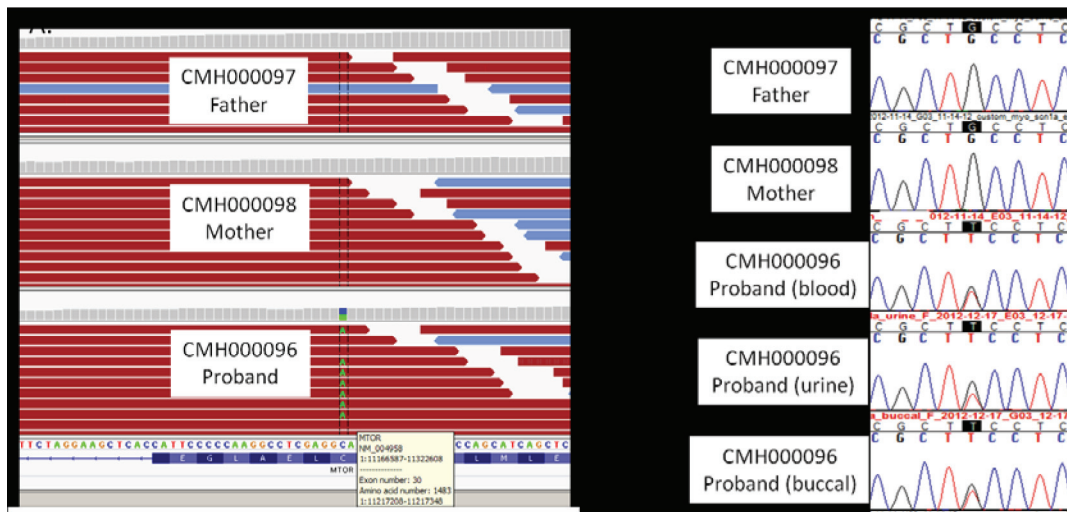
## Sequence analysis

Gapped alignment to the reference nuclear and mitochondrial genome sequences (Hg19 and GRCH37 [NC\_012920.1], respectively) was performed with the Genomic Short-read Nucleotide Alignment Program (GSNAP),<sup>12</sup> and the Genome Analysis Toolkit (GATK)<sup>13</sup> was applied.<sup>5</sup> Variants were called according to the GATK's Best Practices for Variant Detection v3. Briefly, original GSNAP alignments were locally realigned around candidate indels, then duplicate reads were marked and, finally, alignment base quality scores were recalibrated. Using the post-processed alignments, SNP and indels were initially called with the Unified Genotyper then separately filtered. SNPs were additionally processed through the GATK's variant quality score recalibration workflow which builds an adaptive error model using known variant sites and then applies this model to minimize false positive calls. Nucleotide variants were genotyped, annotated for functional significance with RUNEs, and analyzed as described.<sup>5</sup>

## Results

Exome sequencing was performed to a depth of at least 100-fold in the patient (CMH000096), her mother (CMH000097), and her father (CMH000098), resulting in greater than 94% of targeted nucleotides receiving 10-fold or greater coverage (Supplement Table 2). A total of 133,294, 135,191, and 140,924 nucleotide variants were identified in the patient, her mother, and her father respectively, of which 2583 were annotated as potentially deleterious in the proband (as assessed by a deleteriousness classification of 1–3 by the Rapid Understanding of Nucleotide variant Effect Software (RUNES v1.0) (Supplement Table 2)).<sup>5</sup> A total of 21 classification 1–3 variants were found in the 198 genes nominated by SSAGA

(Supplement Table 3). Limiting these variants to only those with an allele frequency of 1% or less resulted in only 2 variants in 2 genes, but neither were in genes associated with a phenotype consistent with this patient's presentation or of the type consistent with recessive or dominant inheritance. Expanding the variants to those located in genes other than those nominated by SSAGA with an allele frequency of 1% or less resulted in a total of 467 variants. Of these variants, 8 had previously been annotated as disease causing, and 25 were of the type likely to disrupt gene function; however, after expert review, none of these variants were considered likely to be associated with the clinical phenotype in this patient. Applying a recessive inheritance pattern to the 467 variants yielded 34 variants in 25 genes. Six genes had homozygous variants (Supplement Table 4), and 17 genes had 2 or more heterozygous variants consistent with an autosomal recessive inheritance pattern (Supplement Table 4). None of these genes were associated with phenotypes consistent with the clinical history. The exome of the proband was then examined for de novo mutations by limiting the analysis to variants not detected in either parent, which yielded 3 genes and variants (Supplement Table 4). Of these, the proband had one heterozygous de novo variant, c.4448G > T (p.Cys1483Phe) in *MTOR* that was phenotypically relevant. The variant was found in 20 of 43 reads (47%) in the patient and not seen in 56 or 57 reads covering that nucleotide position in her mother or father, respectively (Fig. 3). Subsequently, this mutation was confirmed by capillary sequencing to be heterozygous (present in approximately 50% in DNA from peripheral blood leukocytes, a buccal smear, and urine sediment cells from the patient), suggesting that the mutation is likely to be pan-cellular and germline in nature. Capillary sequencing did not identify this variant in peripheral blood DNA or buccal DNA of either parent. A change at this nucleotide position has been reported as a de novo somatic mutation in a patient with hemimegalencephaly wherein varying mutation loads were observed in different brain sections and absent in the blood.<sup>8</sup> While a change from a cysteine (TGT) to a tyrosine (TAT) has been reported,<sup>8</sup> a transversion was identified in our patient that results in a change from a cysteine (TGT) to a phenylalanine (TTT). The cysteine residue is highly conserved among species (Supplement Fig. 1), and



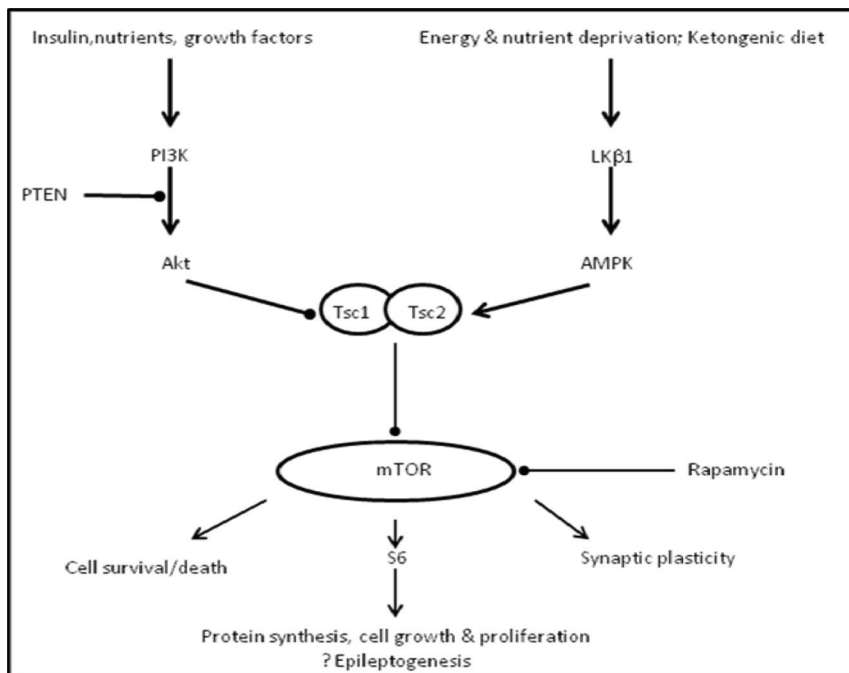
**Figure 3. A.** Next generation sequencing results viewed in the Integrative Genome Viewer<sup>30</sup> of de novo heterozygous variant c.4448 G > T (p.Cys1483Phe) in the *MTOR* gene, found in 20 of 43 reads (47%) in the proband (CMH000096) and absent in the father (CMH000097) and the mother (CMH000098). **B.** Sanger sequencing comparison showing heterozygosity for the c.4448 G > T (p.Cys1483Phe) variant in 3 different sample types isolated from the proband. DNA from peripheral blood, urine sediment, and buccal swabs.

the change is likely to be pathogenic. It has been proposed that a change at this residue results in a gain of function in mTOR.<sup>8</sup>

**Discussion**

The MTOR pathway is highly regulated and critical for cell survival and apoptosis (Fig. 4). MTOR

is a key regulator of protein synthesis, cell growth, and cell proliferation. It also plays a role in synaptic plasticity.<sup>9,10</sup> It is negatively regulated by hamartin and tuberlin, the products of *TSC1* and *TSC2*, respectively. Mutations in either of these genes result in tuberous sclerosis (TS), a condition that presents with hamartomas and epilepsy. *TSC1* and *TSC2* are negatively



**Figure 4.** Simplified PI3K/AKT/mTOR pathway: stimulatory effects (→); Inhibitory effects (–); PIK3-phosphoinositide 3-kinase; PTEN-phosphatase and tensin homolog; LKβ1-liver kinase β1; Akt-B protein kinase B; AMPK-AMP-activated protein kinase; Tsc1-tuberous sclerosis 1; Tsc2-tuberous sclerosis 2; mTOR-mammalian target of rapamycin; S6-ribosomal protein S6.





regulated by PI3K and AKT, both of which have been implicated in hemimegalencephaly syndromes, which are also complicated by epilepsy. This pathway is also regulated by PTEN, mutations in which result in overgrowth and epilepsy. It has been demonstrated in a mouse model that selective deletion of *Pten* in postnatally generated granule cells was sufficient to cause epilepsy.<sup>14</sup> Since no tumors were found in these animals, it was postulated that the deletion of *Pten* resulted in activation of *Mtor* and that this activation was epileptogenic. The exact pathologic mechanism of epileptogenesis remains unclear. It is known that MTOR negatively regulates autophagy in response to growth factors, nutritional status and stress responses.<sup>15</sup> It has been observed in mouse embryonic fibroblasts deleted for *Tsc2* that autophagocytic activity is downregulated.<sup>16,17</sup> McMahon et al have subsequently demonstrated that *Tsc1* and *Pten* knockout mice have impaired autophagy along with recurrent seizures.<sup>18</sup> This was correlated with increased phosphorylation of S6 in the mouse cortex and hippocampus, an indirect marker of *Mtor* hyperactivation. This finding was recapitulated in samples from brains of human patients with tuberous sclerosis. In addition, seizures were much more severe in mice with deletion of *Tsc1* and *Pten* than in mice deleted for *Atg7*, which is directly involved in inhibition of autophagy but is not involved in regulation of *Mtor*. Thus, it would appear that impaired autophagy in neurons is directly related to unregulated expression of MTOR and that this plays some role in epilepsy.

Medical interventions that modulate the PI3K-AKT3-mTOR pathway may prove effective in the management of seizures.<sup>19</sup> The ketogenic diet has been used successfully for the treatment of intractable seizures by both anticonvulsant effect and by preventing, at least in an animal model of status epilepticus, mossy fiber sprouting.<sup>20,21</sup> McDaniel et al demonstrated that the ketogenic diet manifests its effects via inhibition of the MTOR pathway as evidenced by decreased phosphorylation and expression of pS6 and pAkt in the liver and hippocampus of rats maintained on the diet.<sup>22</sup> This also raises the tantalizing possibility that treatment with rapamycin, which inhibits MTOR activity, might be useful in the management of seizure disorders. The effectiveness of rapamycin has been demonstrated in several animal models of chronic epilepsy,<sup>23–26</sup> although its effectiveness as an acute

treatment has not been demonstrated.<sup>27</sup> To date, there has been one published case of the successful use of rapamycin in the management of seizures associated with tuberous sclerosis<sup>28</sup> as well as a recent report of efficacy in prevention of seizures associated with polyhydramnios, megalencephaly, and symptomatic epilepsy syndrome. The latter syndrome results from deficiency of pseudokinase, an upstream inhibitor of *MTOR1*.<sup>29</sup> Thus it is conceivable that treatment of our patient with rapamycin might have been effective. While clinical trials in the use of rapamycin in TS are currently underway, since there is only one report of a gain of function mutation in *MTOR*, the efficacy of rapamycin under such conditions has not been tested.

While de novo germline mutations in *AKT3*, *PIK3R2*, and *PIK3CA* in megalencephaly syndromes have been observed,<sup>8</sup> this report identified only a single case of hemimegalencephaly associated with a de novo somatic cell mutation in MTOR from a cysteine to a tyrosine moiety at residue 1483. This mutation was identified in brain cells after hemispheric resection but was not found in blood leukocytes. It was postulated that this mutation, which changes the same cysteine residue observed in our patient, leads to a gain of function of MTOR. Both phenylalanine and its derivative tyrosine replace an uncharged polar sulfur-containing side chain with a bulky nonpolar side chain and would be expected to disrupt protein conformation. Our case represents the first case wherein a mutation in *MTOR* in a patient with symmetric megalencephaly and seizures has been identified in blood. Furthermore, the mutation was found to be present in both buccal and urine sediment cells, suggesting that the mutation in this child is pancellular. It is also notable that this child, for whom control of seizures was incomplete and required polypharmaceutical intervention, had a tempered response to the ketogenic diet. Since the ketogenic diet is felt to downregulate expression of *MTOR*, this suggests that at some level either increased expression or increased activity of MTOR is playing a role in epileptogenesis. It may be that provision of the ketogenic diet was not completely successful because downregulation of *MTOR* gene expression does not completely counteract the possible gain of function resulting from the mutation. The natural history of individuals with mutations in *MTOR* is unknown. Axial skeletal overgrowth is not affected by mutations in *MTOR*, but megalencephaly



is clearly a finding. It may be that treatment with rapamycin might have resulted in decreasing the rate of rapid head growth in this patient. It is also possible, given the role of MTOR in tumorigenesis, that this child, had she survived, been at risk for solid tumor development and that treatment with rapamycin might have reduced this risk. Just prior to initiation of treatment with rapamycin in an attempt to improve seizure control, the patient developed a respiratory infection requiring hospitalization. She experienced a massive generalized seizure that resulted in obtundation. The difficult decision to remove ventilatory support was made, and the patient expired; thus, we are unable to say what effect treatment with rapamycin may have had on her clinical course.

## Conclusion

Despite this unfortunate outcome, this case study emphasizes the role that new technologies such as exome and whole genome sequencing will play in the future of clinical care and development of personalized treatments. It is interesting to postulate what the clinical course might have been had a mutation in *MTOR* been identified in the neonatal period with subsequent early treatment with rapamycin.

## Acknowledgements

We would like to thank the patient and her family for allowing us to participate in her diagnostic process and care. *A deo lumen, ab amicis auxilium.*

## Funding

This work was supported by the Marion Merrell Dow Foundation, The Children's Mercy Hospitals and Clinics, the Patton Trust and the WT Kemper Foundation.

## Author Contributions

Conceived and designed the experiments: CS, DD, EF, SK. Analysed the data: LS, CS, DD, NM, SS, EF, SK. Wrote the first draft of the manuscript: LS. Contributed to the writing of the manuscript: LS, CS, DD, AA, NM, SS, EF, AA, SK. Agree with manuscript results and conclusions: LS, CS, DD, AA, NM, SS, EF, AA, SK. Jointly developed the structure and arguments for the paper: LS, CS, DD, AA, NM, SS, EF, AA, SK. Made critical revisions and approved final

version: LS, CS, DD, AA, SS, EF, AA, SK. All authors reviewed and approved of the final manuscript.

## Competing Interests

ATGA reports speaking fees from Cyberonics Inc. Other authors disclose no competing interests.

## Disclosures and Ethics

As a requirement of publication the authors have provided signed confirmation of their compliance with ethical and legal obligations including but not limited to compliance with ICMJE authorship and competing interests guidelines, that the article is neither under consideration for publication nor published elsewhere, of their compliance with legal and ethical guidelines concerning human and animal research participants (if applicable), and that permission has been obtained for reproduction of any copyrighted material. This article was subject to blind, independent, expert peer review. The reviewers reported no competing interests.

## References

- Hauser WA, Annegers JF, Kurland LT. Incidence of epilepsy and unprovoked seizures in Rochester, Minnesota: 1935–1984. *Epilepsia*. 1993;34(3):453–468.
- Ottman R. Genetic epidemiology of epilepsy. *Epidemiol Rev*. 1997;19(1):120–128.
- Kingsmore SF, Dinwiddie DL, Miller NA, Soden SE, Saunders CJ. Adopting orphans: comprehensive genetic testing of Mendelian diseases of childhood by next-generation sequencing. *Expert Rev Mol Diagn*. 2011;11(8):855–868.
- Kingsmore SF, Saunders CJ. Deep sequencing of patient genomes for disease diagnosis: when will it become routine? *Sci Transl Med*. 2011;15;3(87):87ps23.
- Saunders CJ, Miller NA, Soden SE, et al. Rapid whole-genome sequencing for genetic disease diagnosis in neonatal intensive care units. *Sci Transl Med*. 2012;4(154):154ra135.
- Ku CS, Polchronakos C, Tan EK, et al. A new paradigm emerges from the study of de novo mutations in the context of developmental disease. *Mol Psychiatry*. 2013;18(2):141–153.
- Rivière JB, Mirzaa GM, O'Roark BJ, et al. De novo germline and postzygotic mutations in AKT3, PIK3R2 and PIK3CA cause a spectrum of related megalencephaly syndromes. *Nat Genet*. 2012;44(8):934–940.
- Lee JH, Huynh M, Silhavy JI, et al. De novo somatic mutations in components of the PI3K-AKT3-mTOR pathway cause hemimegalencephaly. *Nat Genet*. 2012;44(8):941–945.
- Hay N, Sonenberg N. Upstream and downstream of mTOR. *Genes Dev*. 2004;18(16):1926–1945.
- Wong W, Crino PB. MTOR and epileptogenesis in developmental brain malformations. In: Noebels JL, Avoli M, Rogawski MA, Olsen RW, Delgado-Escueta AV, eds. *Jasper's Basic Mechanisms of the Epilepsies*. 4th ed. Bethesda, MD: National Center for Biotechnology Information (US); 2012. <http://www.ncbi.nlm.nih.gov/books/NBK50785/> Accessed July 17, 2013.
- Dinwiddie DL, Miller NA, Saunders CJ, et al. Exome sequencing reveals cause of hypomyelinating leukodystrophy. *J Genome Exome*. 2012;1:7–14.





12. Wu TD, Nacu S. Fast and SNP-tolerant detection of complex variants and splicing in short reads. *Bioinformatics*. 2010;26(7):873–881.
13. DePristo MA, Banks E, Poplin R, et al. A framework for variation discovery and genotyping using next-generation DNA sequencing data. *Nat Genet*. 2011;43(5):491–498.
14. Pun RYK, Rolle OJ, LaSarge CL, et al. Excessive activation of mTOR in postnatally generated granule cells is sufficient to cause epilepsy. *Neuron*. 2012;75:1022–1034.
15. Levine B, Klionsky DJ. Development by self-digestion: molecular mechanisms and biological functions of autophagy. *Dev Cell*. 2004;6(4):463–477.
16. Ng S, Wu YT, Chen B, Zhou J, Shen HM. Impaired autophagy due to constitutive mTOR activation sensitizes TSC2-null cells to cell death under stress. *Autophagy*. 2011;7(10):1173–1186.
17. Parkhitko A, Myachina F, Morrison TA, et al. Tumorigenesis in tuberous sclerosis complex is autophagy and p62/sequestome 1 (SQSTM1)-dependent. *Proc Natl Acad Sci U S A*. 2011;108(30):12455–12460.
18. McMahon J, Huang X, Yang J, et al. Impaired autophagy in neurons after disinhibition of mammalian target of rapamycin and its contribution to epileptogenesis. *J Neurosci*. 2012;32(45):15704–15714.
19. Ryther RCC, Wong M. Mammalian target of rapamycin (mTOR) inhibition: potential for antiseizure, antiepileptogenic, and epileptostatic therapy. *Curr Neurol Neurosci Rep*. 2012;12(4):410–418.
20. Muller-Schwarze AB, Tandon P, Liu Z, Yang Y, Holmes GL, Stafstrom CE. Ketogenic diet reduces spontaneous seizures and mossy fiber sprouting in the kainic acid model. *Neuroreport*. 1999;10(7):1517–22.
21. Su SW, Cilio MR, Sogawa Y, et al. Timing of ketogenic diet initiation in an experimental epilepsy model. *Brain Res Dev Brain Res*. 2000;125(1–2):131–8.
22. McDaniel SS, Rensing NR, Thio LL, Yamada KA, Wong M. The ketogenic diet inhibits the mammalian target of rapamycin (mTOR) pathway. *Epilepsia*. 2011;52(3):e7–e11.
23. Huang X, Zhang H, Yang J, et al. Pharmacological inhibition of the mammalian target of rapamycin pathway suppresses acquired epilepsy. *Neurobiol Dis*. 2010;40(1):193–199.
24. Raffo E, Coppola A, Ono T, Briggs SW, Galanopoulou AS. A pulse rapamycin therapy for infantile spasms and associated cognitive decline. *Neurobiol Dis*. 2011;43(2):322–329.
25. Talos DM, Sun H, Zhou X, et al. The interaction between early life epilepsy and autistic-like behavioral consequences: a role for the mammalian target of rapamycin (mTOR) pathway. *PLoS One*. 2012;7(5):e35885.
26. Zeng LH, Rensing NR, Wong M. The mammalian target of rapamycin signaling pathway mediates epileptogenesis in a model of temporal lobe epilepsy. *J Neurosci*. 2009;29(21):6964–6972.
27. Hartman AL, Santos P, Dolce A, Hardwick JM. The mTOR inhibitor rapamycin has limited acute anticonvulsant effects in mice. *PLoS One*. 2012;7(9):e45156.
28. Muncy J, Butler IA, Koenig MK. Rapamycin reduces seizure frequency in Tuberous Sclerosis Complex. *J Child Neurol*. 2009;24(4):477–78.
29. Parker WE, Orlova KA, Parker WH, et al. Rapamycin prevents seizures after depletion of STRADA in a rare neurodevelopmental disorder. *Sci Transl Med*. 2013;5(182):182ra53.
30. Robinson JT, Thorvaldsdóttir H, Winckler W, et al. Integrative Genomics Viewer. *Nature Biotechnology*. 2011;29(1):24–26.



---

## **Supplementary Data**

**Supplement Table 1.** Genes nominated by SSAGA.

**Supplement Table 2.** Sequencing and enrichment summary.

**Supplement Table 3.** Variant summary.

**Supplement Table 4.** Variants by inheritance type.

**Supplement Figure 1.** Evolutionary conservation of affected cysteine residue across species.