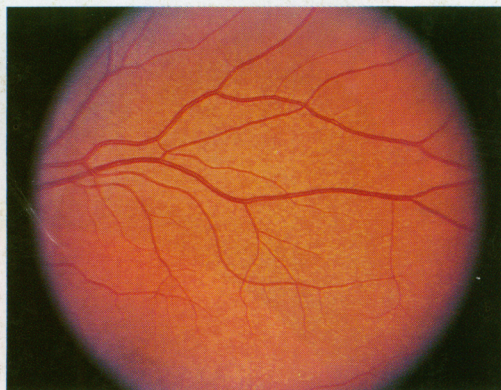
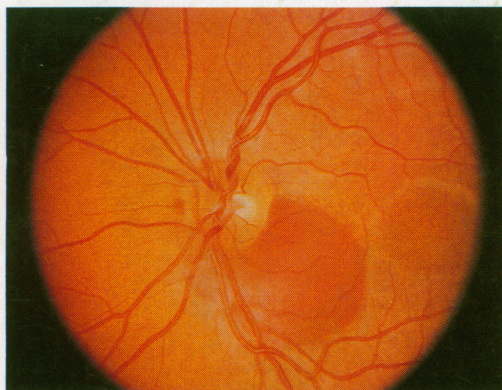


ARCHIVES

OF

FAMILY MEDICINE

MAY 1995



Juxtapapillary subretinal hemorrhage (left) and multiple yellow dots at the level of the retinal pigment epithelium (right). See page 393.

COMMUNICATION BETWEEN PRIMARY CARE PHYSICIANS AND CONSULTANTS

THE USE OF CHILDREN'S DRAWINGS IN THE EVALUATION AND TREATMENT OF CHILD SEXUAL, EMOTIONAL, AND PHYSICAL ABUSE

WOMEN VETERANS' EXPERIENCES WITH DOMESTIC VIOLENCE AND WITH SEXUAL HARASSMENT WHILE IN THE MILITARY

DELIRIUM

FAILURE OF THE COMMUNITY-BASED VITA-STAT AUTOMATED BLOOD PRESSURE DEVICE TO ACCURATELY MEASURE BLOOD PRESSURE

USE OF A 'HEALTH HABITS QUESTIONNAIRE' TO IMPROVE HEALTH PROMOTION COUNSELING

American Medical Association

Physicians dedicated to the health of America



PROPERTY OF
ROBERT M. WHITE MEMORIAL
LIBRARY
PAOLI MEMORIAL HOSPITAL

MALVERN

PA 19355-2123

