

# Trichobezoar: A less suspected diagnosis

Nirhale DS, Athavale VS, Bhatia M, Kurhade S

Department of General Surgery, Padamashree Dr. D. Y. Patil Medical College, Hospital and Research Centre, Pimpri, Pune, Maharashtra, India

## Abstract

Rapunzel syndrome is a rare trichobezoar, involving strands of swallowed hair extending as a tail through the duodenum, beyond the stomach. Trichobezoar usually occur in patients with history of trichotillomania, characterized by compulsive behavioral disorder of pulling own hairs, combined with trichophagia that consists of ingesting that hairs. It typically occurs in the stomach and rarely affects the small intestine. Trichobezoars are more common in adolescent females. Common presentation is a gastrointestinal tract obstruction with nausea, vomiting, gut perforation, hypo chromic anemia, vitamin B12 deficiency, weight loss, an abdominal mass, or other serious problems. Trichobezoar with Rapunzel syndrome is an uncommon diagnosis in children with <40 cases reported. It is predominantly found in emotionally disturbed or mentally retarded youngsters. Trichobezoar is a rare condition that may pose a diagnostic challenge. Patients with this condition often have an underlying psychiatric illness, and history may not be easily forthcoming. The condition should be entertained especially in young females. Delay in diagnosis may lead to futile complications. We present the case of a 14-year-old girl who presented with abdominal pain, vomiting and a nontender abdominal mass.

**Key words:** Rapunzel syndrome, Trichobezoar, Trichophagia

## INTRODUCTION

A bezoar is a mass of undigested material within the gastrointestinal tract. The term bezoar derives from the Arabic word Badzehr, which means antidote.<sup>[1]</sup> Bezoars were used as antidotes against plague, snake-bite, leprosy, and epilepsy by physicians from 12<sup>th</sup> to 18<sup>th</sup> century.<sup>[2]</sup> Trichobezoar is from the Greek word trich which means hair.<sup>[3]</sup> A trichobezoar is a mass of undigested hair within the gastrointestinal tract. Trichobezoars are often associated with trichotillomania (hair pulling), and trichophagia (hair swallowing). Trichotillomania may be unconsciously or unintentionally done and is part of the Diagnostic and Statistical Manual of Mental Disorders IV psychiatric classification of impulse control disorders.<sup>[4,5]</sup> In up

to 18% of patients with trichotillomania, trichophagia occurs; one third of patients with trichophagia develop trichobezoars.<sup>[6]</sup> Trichobezoars most commonly occur in adolescent females.<sup>[7]</sup> The site of hair pulling is most commonly from the scalp, but can occur from the eyelashes, eyebrows, and pubic area.<sup>[8]</sup>

## CASE REPORT

A 14-year-old female patient presented with painless mass in epigastrium since 3 months, associated with fullness in the epigastrium after taking meals. Patient had nausea and vomiting with history of loss of appetite and weight loss. Examination revealed frontal alopecia [Figure 1]. On palpation firm, on tender epigastria mass was felt. Ultrasonography and computed tomography of the abdomen both confirmed the presence of a large gastric mass with internal air loculi involving the entire stomach with extension into the duodenum but not into the jejunum [Figures 2 and 3]. At endoscopy a trichobezoar, involving almost the entire capacity of the stomach, extending from the distal esophagus into the duodenum was noted [Figure 4]. Prompted by these diagnostic findings, on further enquiry, the patient admitted to trichophagia. Due to the size of the trichobezoar and potential for complications, operative

### Access this article online

#### Website:

www.jomip.org

#### DOI:

10.4103/9783-1230.139171

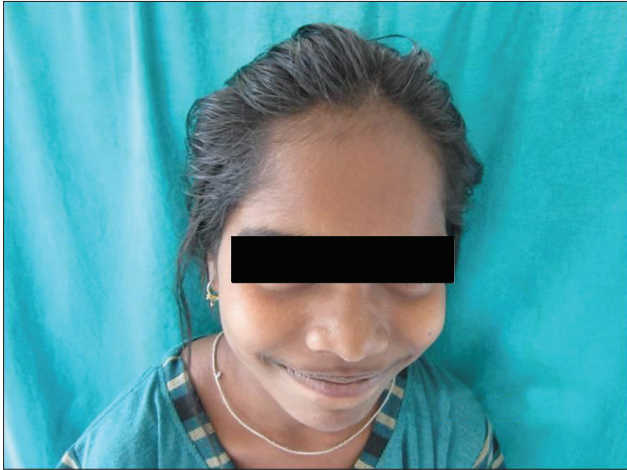#### Quick Response Code



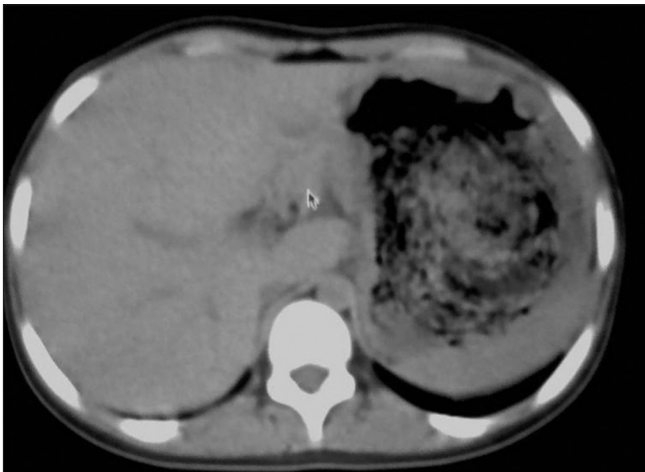#### Address for correspondence:

Dr. Mohit Bhatia, 1, Bank Colony, Opposite Old Sessions Courts, Ambala - 134 003, Haryana, India. E-mail: drbhatia1985@gmail.com

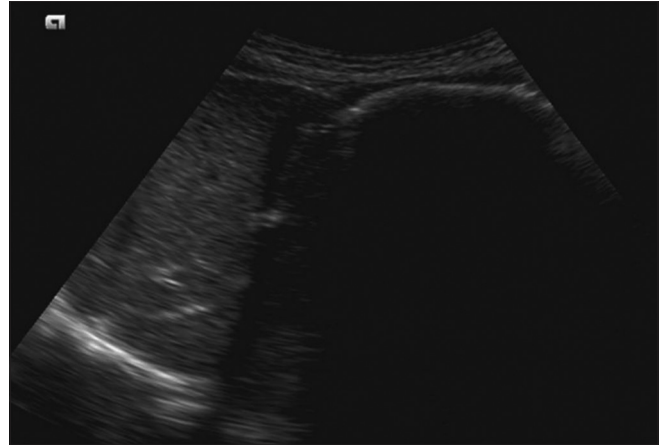
removal of the trichobezoar was undertaken successfully via a gastrostomy [Figures 5-7]. Tuft of hair in shape of stomach weighing 0.7 kg was removed successfully [Figure 8].



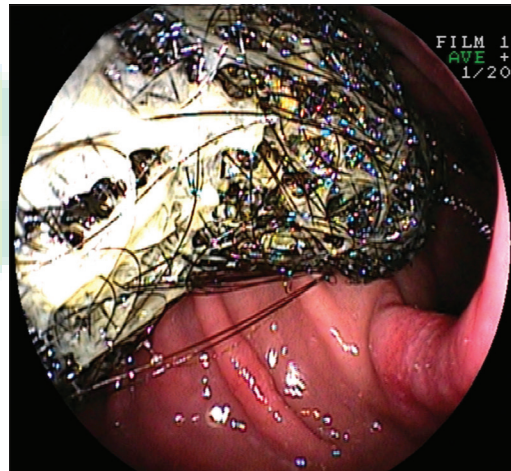
**Figure 1:** 14-year-old girl with frontal alopecia



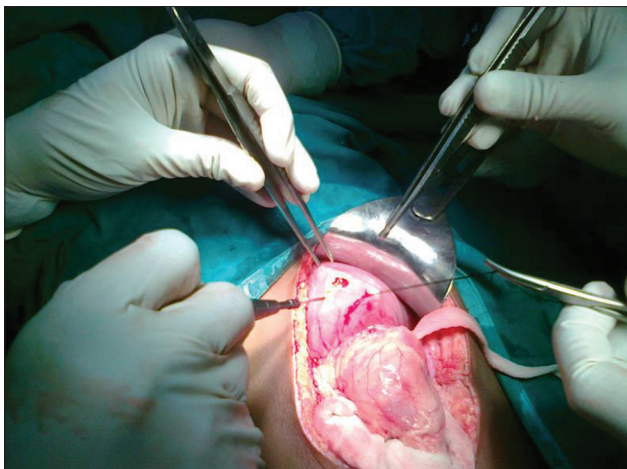
**Figure 3:** Contrast enhanced computed tomography abdomen showing large gastric mass with internal air loculi involving the entire stomach with extension into the duodenum but not into the jejunum



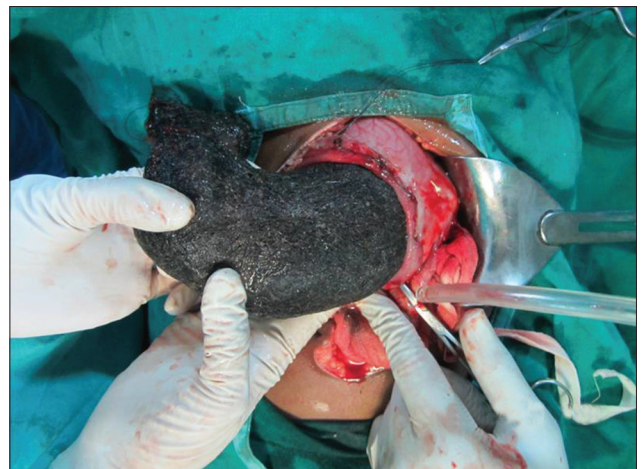**Figure 2:** Ultrasound abdomen showing the presence of a gastric mass



**Figure 4:** Endoscopy confirming the diagnosis of a trichobezoar



**Figure 5:** Intraoperative image showing gastrostomy

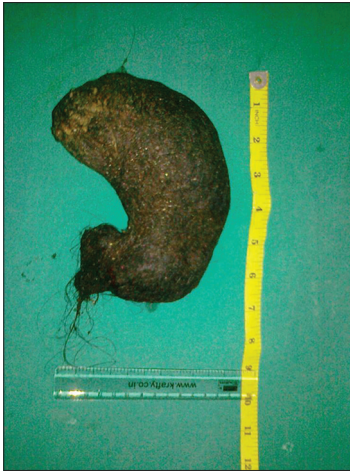

**Figure 6:** Mass being delivered out

## DISCUSSION

A bezoar derived from Persian bazahr, “antidote” is a mass found trapped in the gastrointestinal system (usually the stomach) though it can occur in other locations.<sup>[9]</sup>





**Figure 7:** Hair tuft removed in to



**Figure 8:** Hair tuft measuring 0.7 kg

#### Types

- Lactobezoar
- Pharmacobezoars (or medication bezoars)
- Phytobezoars
- Trichobezoar.

Lactobezoar is a specific type of food bezoar comprising inspissated milk. It is most commonly seen in premature infants receiving formula feeds. Pharmacobezoars (or medication bezoars) are mostly tablets or semi liquid masses of drugs, normally found following overdose of sustained release medications. Phytobezoars- composed of indigestible plant material (e.g., cellulose), and are frequently reported in patients with impaired digestion and decreased gastric

motility.<sup>[10]</sup> Trichobezoar (hair balls) - consists of matted mass of ingested hair that may form a perfect cast of stomach. It remains undigested in the stomach. On occasion mass may project into the duodenum and may extend throughout the bowel (Rapunzel syndrome).<sup>[11]</sup> Usually encountered in the young girl patients. About 10% of patients show some degree of mental disturbance. Etiology is trichophagy (hair swallowing). Hair ball can lead to ulceration, bleeding, perforation and obstruction. Endoscopy is diagnostic. In some cases, small bezoars composed mainly of food substances can be fragmented through the fiber optic endoscope.<sup>[12]</sup> In operative treatment of bezoars it is important to look the remainder of the intestine carefully to ensure complete removal of all foreign bodies. Large trichobezoar may not be amenable to any treatment other than open surgical removal by means of a gastrostomy.

## REFERENCES

1. Samad A, Ahmad M, Latif Z. Bezoars: A review and report of two cases. *J Coll Physicians Surg Pak* 1997;7:263-5.
2. Khattak S, Asghar K. Trichobezoar. *Gomal J Med Sci* 2004;2:25-6.
3. Rabie ME, Arishi AR, Khan A, Ageely H, Seif El-Nasr GA, Faghihi M. Rapunzel syndrome: The unsuspected culprit. *World J Gastroenterol* 2008;14:1141-3.
4. American Psychiatric Association. *Diagnostic and Statistical Manual of Mental Disorders*. Washington, DC: American Psychiatric Association; 2000.
5. Christenson GA, Crow SJ. The characterization and treatment of trichotillomania. *J Clin Psychiatry* 1996;57 Suppl 8:42-7.
6. Bouwer C, Stein DJ. Trichobezoars in trichotillomania: Case report and literature overview. *Psychosom Med* 1998;60:658-60.
7. Phillips MR, Zaheer S, Drugas GT. Gastric trichobezoar: Case report and literature review. *Mayo Clin Proc* 1998;73:653-6.
8. Christenson GA, Mackenzie TB, Mitchell JE. Characteristics of 60 adult chronic hair pullers. *Am J Psychiatry* 1991;148:365-70.
9. Bala M, Appelbaum L, Almog G. Unexpected cause of large bowel obstruction: Colonic bezoar. *Isr Med Assoc J* 2008;10:829-30.
10. Pitiakoudis M, Tsaroucha A, Mimidis K, Constantinidis T, Anagnostoulis S, Stathopoulos G, et al. Esophageal and small bowel obstruction by occupational bezoar: Report of a case. *BMC Gastroenterol* 2003;3:13.
11. Mintchev MP, Deneva MG, Aminkov BI, Fattouche M, Yadid-Pecht O, Bray RC. Pilot study of temporary controllable gastric pseudobezoars for dynamic non-invasive gastric volume reduction. *Physiol Meas* 2010;31:131-44.
12. Gorter RR, Kneepkens CM, Mattens EC, Aronson DC, Heij HA. Management of trichobezoar: Case report and literature review. *Pediatr Surg Int* 2010;26:457-63.

**How to cite this article:** Nirhale DS, Athavale VS, Bhatia M, Kurhade S. Trichobezoar: A less suspected diagnosis. *J Med Investig Pract* 2014;9:87-9.  
**Source of Support:** Nil, **Conflict of Interest:** None declared.